

Early Decompression In Traumatic Cervical Dislocation Improve Patient Neurology Outcome

¹Leong JF, ¹Rhani SA, ¹Baharudin A, ¹Ariffin HM
¹Orthopaedic Department, Hospital University Kebangsaan Malaysia

INTRODUCTION:

There have been vast numbers of studies looking at the timing of surgical intervention for traumatic spinal cord injuries but still no consensus has been reached on the optimum timing of spinal decompression surgery. A review of the current literature reveals varying results with some indicate potential neurological benefit associated with “early” decompression, while others do not. We have demonstrated that early surgical intervention within 24 hours in our patient with cervical dislocation improve neurological outcome without any complications.

CASE REPORT:

We present a case of a 23 year old gentleman who sustained C5/C6 fracture dislocation during rugby match. Post trauma he complained of bilateral upper and lower limbs weakness with reduced sensation on all limbs. His upper limb power were grade 3 from C5 to T1 bilaterally and lower limb were 0 from L2 to S1 bilaterally. His sensation was reduced from C7 to T2 and absent from T3 downwards bilaterally. Anal tone was intact. Urgent CT and MRI of his c-spine have shown comminuted left C5 posterior element fracture with disruption of the left C5/C6 facet joint causing anterolisthesis and significant spinal canal stenosis at C5/C6 level complicated by spinal cord compression and oedema.

He was diagnosed with C5/C6 fracture dislocation with incomplete neurology ASIA C (American Spinal Injury Association). Spinal cord decompression and posterior instrumentation with fusion from C3 to C7 was done within 12 hours from time of injury. At post-operative day 5 he regained almost normal power to his bilateral upper limb and right lower limb with some residual weakness on left lower limb (L2-S1).

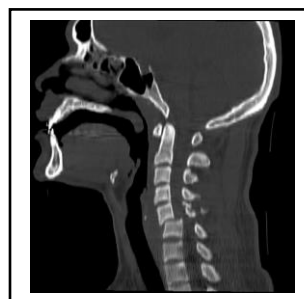

Figure 1: CT imaging showing comminuted C5 posterior element fracture with anterolisthesis of C5 over C6.

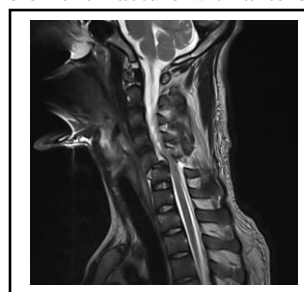


Figure 2: T2-weighted magnetic resonance imaging sagittal view, showing subluxation of C5 over C6 (about 50% anterior translation) causing spinal canal narrowing and spinal cord compression.

DISCUSSIONS:

A systemic review by Mahmoud Yousefifard et al (1), have shown that early decompression surgery, within 24 hours of injury, is associated with improved neurologic recovery compared to late intervention. Another study STASCIS (Surgical Timing in Acute Spinal Cord Injury Study) have concluded that decompression prior 24 hours after SCI can be performed safely and is associated with improved neurologic outcome, defined as at least 2 grade AIS improvement at 6 months follow-up (2).

CONCLUSION:

In conclusion, decompression surgery prior 24 hours when performed safely can be associated with improved neurologic outcome defined as at least 2 grade AIS improvement as shown in our case.