

## “Postural Kyphoscoliosis”: An Atypical Presentation Of Herniated Lumbar Nucleus Pulposus

<sup>1</sup>Kow RY, <sup>1</sup>Hazwan AW, <sup>1</sup>Ed Simor Khan, <sup>1</sup>Colin K, <sup>1</sup>Low CL  
<sup>1</sup>Orthopaedic, Hospital Tengku Ampuan Afzan, Kuantan, Pahang

### INTRODUCTION:

Herniated Nucleus Pulposus is displacement of disc material beyond the intervertebral disc normal margins resulting in pain, weakness or numbness following the myotomal or dermatomal distribution. We present a patient with severe L4/L5 herniated nucleus pulposus who presented with “postural kyphoscoliosis”

### CASE REPORT:

Mr YMC, a 22-year-old healthy gentleman presented with abnormal posture and back pain for 3 months. There was no history of trauma. Clinically the “kyphoscoliosis” was postural due to severe back pain on straightening the back. On examination, straight leg raising test was positive with L4 myotomal symptoms. Plain radiograph of the thoracolumbar region did not reveal any deformity. The magnetic resonance imaging of lumbosacral revealed a herniated lumbar nucleus pulposus over the L4/L5 region, impinging on the L4 exiting nerve root. The patient underwent laminectomy L4 and discectomy L4/5 without any complication. Post-operatively, the patient recovered well with normal posture.

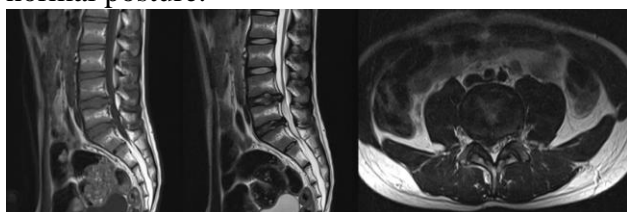


Figure A: Magnetic resonance imaging of the lumbosacral show a severe herniated nucleus pulposus over the L4/L5 region.

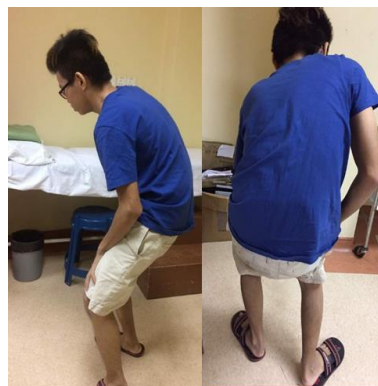

Figure B shows the abnormal posture of the patient upon presentation to the clinic.

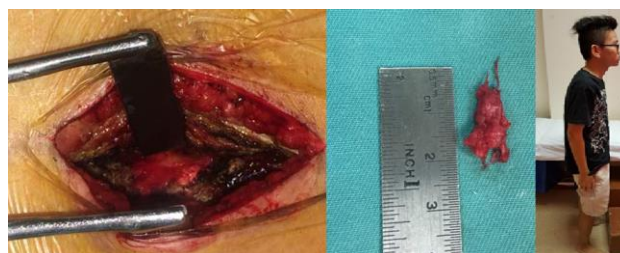

Figure C shows intra-operative figure and the removed nucleus pulposus and the patient recover with normal posture after the surgery.

### DISCUSSIONS:

It is still controversial in terms of outcomes of medical and or physical therapy compared to surgical intervention in herniated nucleus pulposus. In those patient that warrant surgical intervention, patient with age<40 and surgery within 6 months would predict a good surgical outcomes. In our patient, the surgery improves the motor function, correct the posture and improve his quality of life.

### CONCLUSION:

This case highlights the surgical role in terms of managing patients with prolapsed nucleus pulposus that failed conservative management. Early surgical intervention yields a good functional outcome in those patient with severe disease.