

## Congenital Muscular Torticollis Released By Modified Ferkel's Procedure

<sup>1</sup>Goh TC, <sup>1</sup>Saw XY, <sup>1</sup>Ahmad Faizal A, <sup>1</sup>Sivapathasundaram N  
<sup>1</sup>Orthopaedic, Hospital Melaka, Jalan Mufti Hj Khalil 75400 Melaka

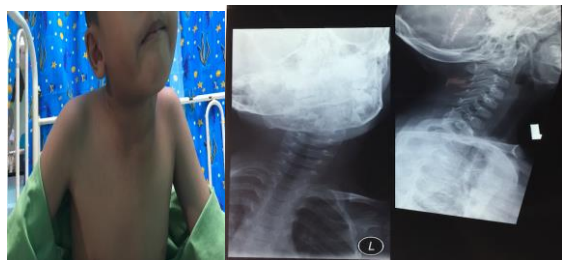### INTRODUCTION:

Congenital muscular torticollis results from shortening or excessive contraction of sternocleidomastoid (SCM) muscle. The deformity is characterized by painless, contracted cordlike SCM muscle, which pulls the head toward the side affected, narrows and draws the shoulder upward, forcing the chin in opposite direction.

Torticollis, by definition means a deformity (congenital or acquired), characterized by lateral inclination of head to shoulder, with torsion of the neck and deviation of face. Muscular torticollis being the most common form, results from shortening or excessive contraction of SCM muscle.

### CASE REPORT:

A 7 years old boy, affected with congenital muscular torticollis was born with no positive family history for muscular torticollis. Congenital muscular torticollis was diagnosed in first year of life. He had undergone physiotherapy of active neck stretching exercise at the age of 2 to 3 months old till the age of one with no improvement. A complete neurologic examination revealed a normal study. Preoperative cervical and chest radiograph revealed normal cervical lordosis, no evidence of maldevelopment or subluxation of cervical vertebra.

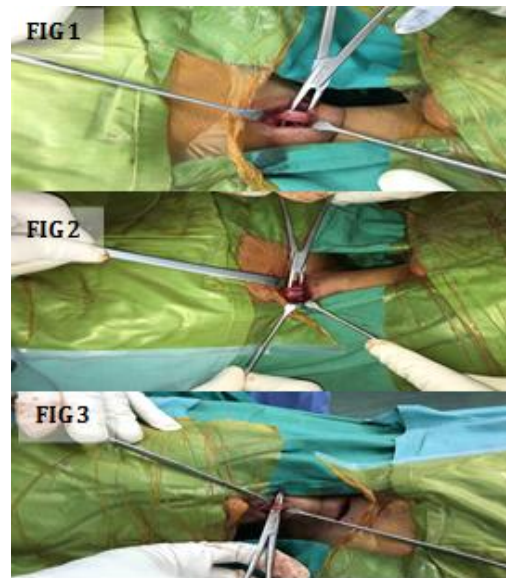


### DISCUSSION:

Bipolar release was performed by using modified Ferkel's procedure by releasing of both inferior and superior head of SCM muscle. Inferior release was done through an incision 1cm above the medial third of clavicle. Clavicular head was released completely (FIG 1) while the sternal head was lengthened by Z-plasty. (FIG 2) The mastoid

head was released through an incision just below the tip of mastoid process. (FIG 3) All tight fascial sheaths were released, taking due precaution not to injure any neurovascular structure.

### CONCLUSION:



We believe that bipolar release is a very viable option for correcting congenital muscular torticollis. The procedure is much more effective than unipolar release or subcutaneous tenotomy and is relatively complication free and safe. Lengthening of sternal head by Z-plasty restores the V-shape of base of neck, which adds to the cosmetic especially in a female patient. We had done 3 cases of bipolar release and Z-plasty for the patient with congenital muscular torticollis with good outcome.

### REFERENCES:

1. J. S. Shim, H. P. Jang. Operative treatment of congenital torticollis. Bone & Joint Journal Jul 2008, 90-B (7) 934-939
2. K. F. Hulbert. Congenital torticollis. Bone & Joint Journal Feb 1950, 32-B (1) 50-59