

Hemicortical Allograft Ankle Arthrodesis: A Novel Limb Salvage Technique For Distal Tibia Chondrosarcoma

¹Chew YW, ¹Narhari P, ¹Azid A, Osman Z
¹Orthopaedic Department, Hospital Pualu Pinang

INTRODUCTION:

Chondrosarcoma is the second most common primary malignant bone tumour occurring among older patients within the long bones. Chondrosarcoma of distal tibia poses a challenge to treat due to poor tissue coverage. This case describes successful distal tibia resection with osteoarticular allograft and ankle arthrodesis reconstruction.

CASE REPORT:

23 years old lady presented with 5 years of right ankle pain. Imaging showed a cystic lesion measuring 2cm x1.5cm over the distal tibio-fibula region. Open biopsy revealed low grade chondrosarcoma.

Hemicortical resection of distal tibia with adjacent fibula was done to achieve clear surgical margin. Distal tibia allograft was used to reconstruct the bony defect. Patient's right lower limb was immobilized with below knee cast. A year later, she was pain-free and able to weight bear. MSTS score at last follow-up was 83%. X-ray showed allograft union (Figure 2) with no local recurrence.

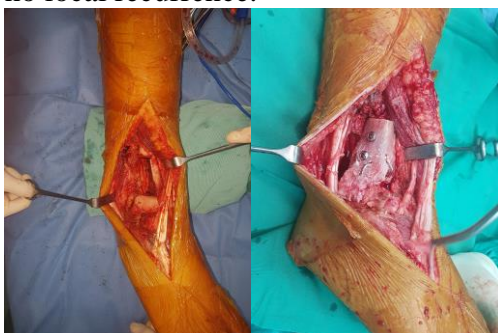


Figure 1: Intra-operative pre- and post-allograft reconstruction

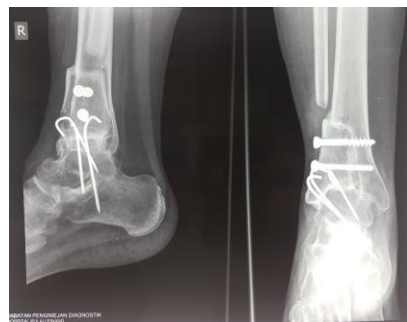

Figure 2: Post op 1 year x-ray shows bone union

DISCUSSION:

Distal tibia sarcomas are commonly treated by 1) resection with distal tibia allograft, 2) resection with distal tibia endoprosthesis or 3) amputation. Despite restricted ankle joint movement, ankle arthrodesis with non-vascularised allograft is effective with good functional results.¹ Endoprosthesis reconstruction in distal tibia to preserve joint movement, has shorter recovery time and lesser risk of non-union.² Our case is unique as we used a hemicortical medial distal tibia allograft to reconstruct a hemicortical lateral distal tibia defect which needed the fibula to be resected as well. With this technique, we were able to address the medial and lateral stability. The end result was a stable ankle with “dual” medial malleoli (figure2).

CONCLUSION:

Allograft ankle arthrodesis is a good and cheap limb salvage alternative to endoprosthesis in the treatment of distal tibia tumours with satisfactory functional score.

REFERENCES:

1. Campanacci DA et. al. Ankle Arthrodesis with Bone Graft after Distal Tibia Resection for Bone Tumours. Orthopaedic Proceedings Mar 2009,91-B (SUPP I)21
2. V Ajit Singh et. al. Endoprosthetic reconstruction for giant cell tumors of the distal tibia: A short term review. Asia-Pacific Journal of Clinical Oncology 2012.doi10.1111/j.1743-7563.2012.01553.x