

## CASE SERIES

# De Novo Focal Segmental Glomerulosclerosis (FSGS) Post Covid 19 Vaccination: Case Series in A Single Centre in Malaysia

Jonathan Thian Hooi Yong<sup>1</sup>, Xun Quan Sze<sup>1</sup>, Christopher Thiam Seong Lim<sup>2</sup>, Bak Leong Goh<sup>1,3</sup><sup>1</sup> Department of Medicine, Sultan Idris Shah Hospital, Jalan Puchong, 43000 Kajang, Selangor Malaysia<sup>2</sup> Nephrology Unit, Department of Medicine, Faculty of Medicine and Health Sciences, Universiti Putra Malaysia, 43400 Serdang, Selangor, Malaysia<sup>3</sup> Clinical Research Centre, Sultan Idris Shah Hospital, Jalan Puchong, 43000 Kajang, Selangor Malaysia

## ABSTRACT

**Introduction:** Mass COVID-19 vaccination has been pivotal in the fight against this pandemic. The occurrence of glomerular disease following COVID-19 vaccinations particularly mRNA vaccine has been reported. The reported cases in the region are limited and number of cases reported are low in contrast to the total number of vaccine doses given worldwide, the healthcare providers should be alerted about such issues to provide swift and proper management. **Case Series:** Here, we report 3 cases of Focal segmental glomerulosclerosis (FSGS) following COVID-19 vaccination and their outcomes. Two of the patients received BNT162b2 vaccination and one received CoronaVac vaccination. The mean age of the patients was 33+/-7 years old. The mean duration onset of FSGS was 23+/-19 days post vaccinations. Two of the patients (BNT162b2 vaccination and CoronaVac vaccination) achieved complete remission after corticosteroid therapy. This is the first reported case of De Novo FSGS following CoronaVac vaccination in the literature. The third patient, who received BNT162b2 vaccination and presented late (42 days post vaccination) was not in remission despite three months of immunosuppressive treatment. **Conclusion:** The treating physician needs to be aware of the possibility of the development of FSGS associated with COVID-19 vaccination and how to proceed with vaccination schedule in these populations. Overall, the advantage of COVID-19 vaccination far outweighs the possibility of COVID-19 vaccine-associated glomerular disease.

*Malaysian Journal of Medicine and Health Sciences* (2023) 19(6):360-363. doi:10.47836/mjmhs.19.6.47

**Keywords:** COVID-19, vaccination, focal segmental glomerulosclerosis (FSGS), kidney biopsy

**Corresponding Author:**

Christopher Lim, FRCP

Email: christopher@upm.edu.my

Tel: +603-97692568

## INTRODUCTION

Coronavirus disease 2019 (COVID-19) emerged in late 2019 and rapidly spread worldwide including Malaysia. Consequently, COVID-19 has become a worldwide pandemic, with report of almost 513 million cases as of May 2022 and up to 6.23 million fatalities. Rapid and mass Covid-19 vaccination had been one of the pivotal strategies to curb this pandemic. As of 26 April 2022, a total of 11,477,767,378 vaccine doses have been administered worldwide (1). The available vaccines are of four types, either inactivated viral vaccine, RNA and DNA vaccine, viral vector vaccine and protein based vaccine. In Malaysia, the COVID-19 vaccination programme was implemented in early March 2021, and by 1/5/2022, a total of 70.3 million doses had been given to the Malaysian population (2). Ever since mass scale COVID-19 vaccination started, several cases of immune-mediated reaction had been reported including

myocarditis, de Novo or relapsed glomerulonephritis (3). De Novo glomerulonephritis which had been reported were IgA nephropathy, Focal segmental glomerulosclerosis (FSGS), minimal change disease, ANCA vasculitis and anti-GBM disease (1). COVID-19 vaccines have been reported to trigger T-cells (4). Hence, the phenomenon of glomerular disease following inoculation of a COVID-19 vaccine can be correlated to the T-cell-mediated immune response which can set off podocyte injury (4). Here, we report a case series of De Novo FSGS after COVID-19 vaccination from a single centre in Malaysia.

## CASE SERIES

**Case 1**

A healthy 41-year-old lady presented with a first onset of bilateral lower limb and facial swelling for the past one month. She had no known family history of kidney diseases. She had received her first dose of CoronaVac vaccine three days before the onset of her symptoms. The laboratory examination revealed a serum creatinine of 112 µmol/L, albumin level of 10g/L, UFEME shows protein 3+ with no hematuria and 24 hours urinary

protein of 11 gram. Autoimmune and infective screening were negative. A kidney biopsy performed around six weeks after vaccination showed focal segmental glomerulosclerosis (collapsing pattern) with negative staining in the immunofluorescence study. She was started on oral prednisolone of 1mg/kg/day with full recovery of renal function and attained complete remission after 3 months of treatment.

**Case 2**

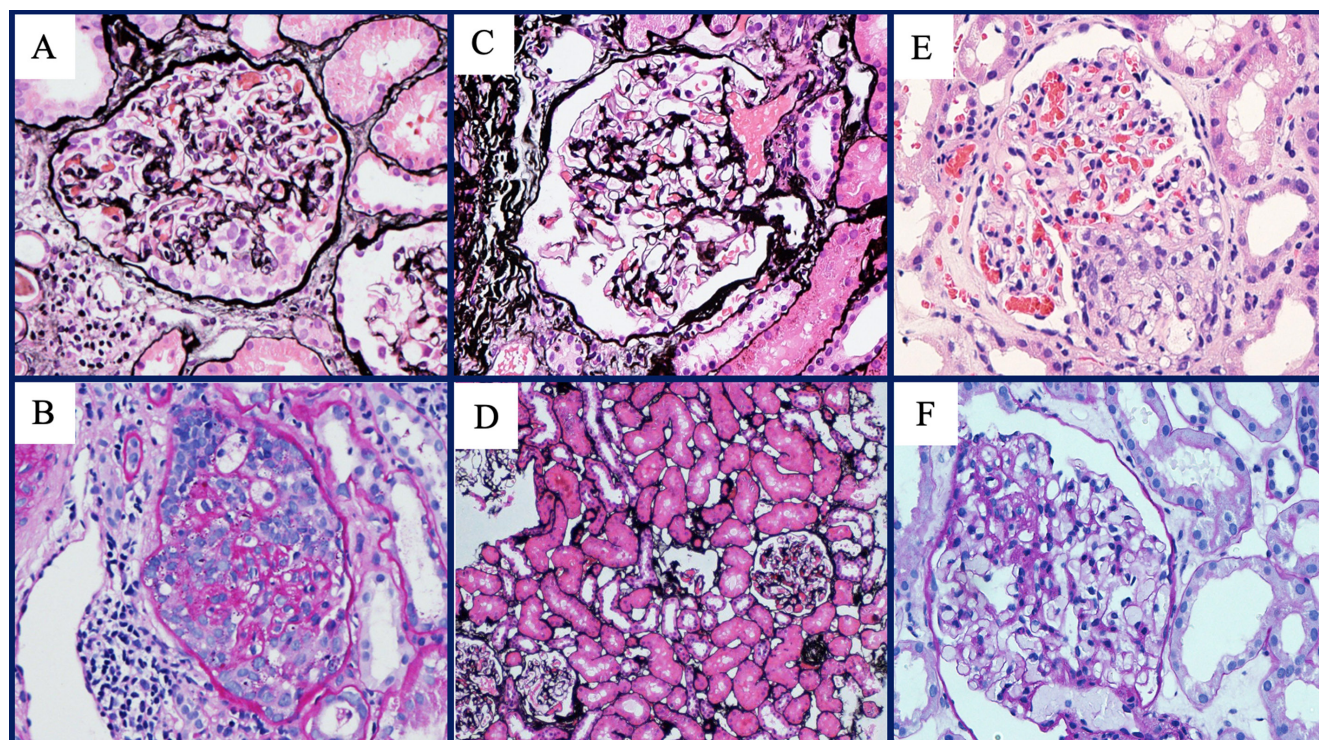
A healthy 28-year-old gentleman presented with first onset of lower limb swelling for four days. He had no known family history of kidney diseases. He had recently received BNT162b2 booster vaccine 25 days prior. The laboratory examination revealed serum creatinine of 81µmol/L, albumin of 17 g/L with UFEME showing no blood and protein 4+. His 24 hours urinary protein was 8.6 gram. Both autoimmune and infective screening were negative. Renal biopsy was done 28 days post vaccination and showed focal segmental glomerulosclerosis (non otherwise specific pattern) with negative staining on immunofluorescence study. He was started on oral prednisolone of 1mg/kg/day and went into complete remission after 3 months of treatment.

**Case 3**

A 32-year-old gentleman with history of COVID-19

infection six months ago which he recovered well from, presented with first onset of bilateral lower limbs, scrotal swelling and facial puffiness for one week. He denied taking any NSAIDs or traditional medication. Of note, he had recently received his third dose of BNT162b2 vaccine just 6 weeks prior. He noticed the symptoms appeared 41 days post vaccination. On examination, he had bilateral pedal oedema until the knee, with abdomen distension and ascites, as well as bibasal crepitations. Laboratory investigations showed: creatinine 87 µmol/L, serum albumin 10 g/L, Total cholesterol 24.17 mmol/L, UFEME shows protein 3+, no haematuria and 24 hours urinary protein is 11 grams. The infective and immunological screening were negative. The kidney biopsy done 41 days after vaccination showed focal segmental glomerulosclerosis (tip variant) with minimal patchy (<5%) chronic tubulointerstitial damage with negative staining in the immunofluorescence study. He was put on steroid treatment (prednisolone at 1mg/kg); however after three months of treatment, there was still no response. Additionally, he had also developed steroid toxicity and hence was started on cyclosporin. Unfortunately he defaulted subsequent follow up.

The summary of the 3 cases is illustrated in Figure 1 and Table I.



**Figure 1: Kidney Biopsy findings.**

- (a) Periodic Acid Silver stain shows FSGS (collapsing variant) characterised by segmental or global obliteration of the capillary tuft associated with wrinkling and collapsing of the glomerular basement membrane. (Magnification x 300, case 1)
- (b) Periodic acid–Schiff stain shows FSGS (collapsing variant) (Magnify x 300, case 1)
- (c) Periodic Acid Silver stain shows Focal Segmental Sclerosis (Magnify x 300, case 2)
- (d) Periodic Acid Silver stain show Focal global sclerosis (Magnify x 100, case 2)
- (e) Hematoxylin and Eosin stain (f) PAS stain show FSGS (tip variant) characterised by segmental lesion involving the tip domain with adhesion between the tuft and Bowman’s capsule at the tubular lumen or neck, (Magnify x 400, case 3)
- (f) Periodic Acid Silver stain show FSGS (tip variant) (Magnify x 300, case 3)

**Table 1: Summary of the reported cases**

	Case 1	Case 2	Case 3
<b>Clinical Presentation</b>			
Age, yr/gender/ Race	41yo/ F/ Indonesian	28yo/ M/ Malay	32yo/ M/ Malay
Medical history	None	None	History of covid infection June 2021
Vaccine/ manufacturer	CORONOVAC (SINOVAC)	BNT162b2 (Pfizer)	BNT162b2 (Pfizer)
Dose (1 <sup>st</sup> /2 <sup>nd</sup> / booster)	1 <sup>st</sup> dose	Booster dose	Booster dose
Temporal association of symptoms to vaccine, days	3 days	25 days	41 days
Symptoms or signs	Nephrotic syndrome, AKI	Nephrotic syndrome	Nephrotic syndrome
Bp, mmHg	113/80	104/61	135/85
<b>Laboratory results</b>			
Serum creatinine, µmol/L	112	81	87
Urinary sediment	Protein 3+	Protein 4+	Protein 3+
24h urinary protein, g/day	11	8.6	11
Serum albumin, g/L	10	17	10
Dyslipidemia	Yes	Yes	Yes
Immunological studies	Negative	Negative	Negative
<b>Histopathology Report</b>			
Glomeruli	28G; 2 global sclerosis, 8 segmental glomerulosclerosis (28%), with collapsing pattern	39G, 1 global sclerosis, 1 segmental glomerulosclerosis	26G; 6 segmental glomerulosclerosis, tip variant
Tubules and Interstitium	Mild IFTA	Minimal IFTA	Minimal IFTA
Vessels	Mild to moderate intimal thickening	Mild to moderate intimal thickening	Mild to moderate intimal thickening
IF	Negative	Negative	Negative
Treatment	Corticosteroids	Corticosteroids	Corticosteroids + cyclosporin
Follow up	Relapsed x 1 and Partial remission at 52 week	Complete remission at 52 weeks	No remission at 12 weeks and defaulted

G, glomeruli; IF, immunofluorescence; IFTA, interstitial fibrosis and tubular atrophy

## DISCUSSION

BNT162b2, also known as the Pfizer-BioNTech COVID-19 vaccine, is a messenger RNA (mRNA) vaccine that encodes the spike protein of the SARS-CoV-2 virus. It requires two doses and has shown to be highly effective in preventing COVID-19 in clinical trials.

Coronavac, on the other hand, is an inactivated virus vaccine and it also requires two doses and has shown to have a lower efficacy rate compared to other COVID-19 vaccines, although it is still effective in preventing severe disease and hospitalization. The lower efficacy of Coronavac may lead to a lesser degree stimulation of host immune system that could otherwise trigger glomerulonephritis. Post-vaccine glomerular disease is a relatively rare condition in Malaysia. Worldwide, there have been reports of minimal change disease occurring after influenza, tetanus and pneumococcal vaccination (4). However, the pathophysiological mechanisms responsible have not been determined. Most cases of COVID-19 vaccine-associated glomerular disease (CVAGD) have been reported following mRNA-based vaccine and adenovirus vector deliveries (1). Both vaccines, albeit using different technology have identical end result of stimulating recipient's cells to

produce the virus spike protein (3). These vaccines can trigger a strong innate and adaptive immune response involving both T and B cells, where T cell activation following foreign mRNA will produce cytokines which could trigger podocytopathies and amplify production of disease-specific antibody by B-cells in certain individuals (5,7). A majority of published cases on CVAGD have being IgA nephropathy and minimal change disease and it is noteworthy that FSGS associated with COVID-19 vaccination have not been widely reported worldwide (2-7). The reported cases of FSGS associated with COVID-19 have presented with nephrotic syndrome that occurred between seven days to three weeks after BNT162b2 vaccination and they all responded well to immunosuppression (3,5-7). The case series we are reporting appears to be similar as well. To the best of our knowledge, case number one in our case series is the first reported case of De Novo FSGS associated with the inactivated CoronaVac vaccine. In regards to Case three, our patient previously received two doses of BNT162b2 vaccine with no complication. However, he developed FSGS after his third dose of BNT162b2 vaccine. This may be explained by the "two hit theory" in which a "first hit" was when he contracted COVID-19 infection despite two vaccinations and remained asymptomatic whereas the "second hit" was following his third dose of BNT162b2 vaccine which may result in abnormal

T-cell regulation and manifestation of podocytopathy (8). There is currently no diagnostic test available to confirm that these glomerulopathies were caused by the COVID-19 vaccine. However, the temporal association of these de-Novo FSGS occurring in otherwise healthy individuals following COVID-19 vaccination may suggest this possibility and is consistent with the reported onset ranging from one day to six weeks (3,4,6). In our case series, we assigned a category of “possible” based on the World Health Organization-Uppsala Monitoring Centre (WHO-UMC) criteria for causality assessment. This is because we were unable to demonstrate clinical improvement with time after vaccination as the patients were started on treatment upon diagnosis. Risk of glomerular disease from vaccination should not be a detriment as most cases were easily treated with standard therapy (3-7). Furthermore, the likelihood of glomerular disease from vaccination appears to be less compared with from COVID-19 infection (5). Hence, the advantage of COVID-19 vaccination far outweighs the possibility of CVAGD. Nevertheless, the appearance of FSGS in all three cases can still be a chance occurrence and a definitive association can only be made when all reported cases in the future are gathered and analysed in a concerted manner.

## CONCLUSION

COVID-19 vaccines have been proven to be safe, effective and life-saving. They have been a crucial tool in this pandemic response and protects against severe disease and death. As the worldwide COVID-19 vaccination campaign continues, we will probably continue to see CVAGD. In Malaysia, De Novo or relapsing glomerulonephritis post vaccination has not frequently been reported. The treating physician/nephrologists needs to be aware of the possibility of the development of FSGS associated with COVID-19 vaccination and how to proceed with vaccination schedule in these populations. Whether these patients if to be scheduled for yearly vaccination, should they be switched to other types of vaccine (from mRNA to adenoviral vector based vaccine) as relapsing glomerulonephritis after rechallenge with the same type of vaccine had been reported (5). In conclusion, as mass vaccination continues, we should be aware of the

association of De Novo or relapsing glomerulonephritis post-vaccination.

## REFERENCES

1. Mathieu E, Ritchie H, Ortiz-Ospina E, Roser M, Hasell J, Appel C, Giattino C, Rod s-Guirao L. A global database of COVID-19 vaccinations. *Nature human behaviour*. 2021 Jul;5(7):947-53. doi: org/10.1038/s41562-021-01122-8
2. Elnaem MH, Mohd Taufek NH, Ab Rahman NS, Mohd Nazar NI, Zin CS, Nuffer W, Turner CJ. COVID-19 vaccination attitudes, perceptions, and side effect experiences in Malaysia: do age, gender, and vaccine type matter?. *Vaccines*. 2021 Oct 9;9(10):1156. doi.org/10.3390/vaccines9101156
3. Klomjit N, Alexander MP, Fervenza FC, Zoghby Z, Garg A, Hogan MC, et al. COVID-19 vaccination and glomerulonephritis. *Kidney international reports*. 2021 Dec 1;6(12):2969-78. doi: 10.1016/j.ekir.2021.09.008
4. Li NL, Coates PT, Rovin BH. COVID-19 vaccination followed by activation of glomerular diseases: does association equal causation?. *Kidney International*. 2021 Nov 1;100(5):959-65. doi: 10.1016/j.kint.2021.09.002
5. Bomback AS, Kudose S, D’Agati VD. De novo and relapsing glomerular diseases after COVID-19 vaccination: what do we know so far? *American Journal of Kidney Diseases*. 2021 Oct 1;78(4):477-80. doi: 10.1053/j.ajkd.2021.06.004
6. Timmermans SA, Busch MH, Abdul-Hamid MA, Frenken LA, Aarnoudse AJ, van Paassen P. Primary Podocytopathies After COVID-19 Vaccination. *Kidney International Reports*. 2021. doi: 10.1016/j.ekir.2021.12.023
7. Lim CA, Lee HS, Yoon S, Kim EJ, Seo JW, Koo JR, et al. Focal segmental glomerulosclerosis following the Pfizer-BioNTech COVID-19 vaccine. *Kidney Research and Clinical Practice*. 2022 Mar;41(2):263. doi: 10.23876/j.krcp.21.308
8. Shimada M, Araya C, Rivard C, Ishimoto T, Johnson RJ, Garin EH. Minimal change disease: a “two-hit” podocyte immune disorder? *Pediatric Nephrology*. 2011 Apr;26(4):645-9. doi: 10.1007/s00467-010-1676-x