

## CASE REPORT

# Intermittent EGFR-TKI Therapy is Associated with Durable Response in Advanced EGFR-Mutant NSCLC: A Case Report

Sin Nee Tan<sup>1</sup>, Aishah Ibrahim<sup>1</sup>, Megat Razeem Abdul Razak<sup>1</sup>, Muhammad Naimuddin Abdul Azih<sup>2</sup>, Soon Hin How<sup>2</sup>

<sup>1</sup> Department of Internal Medicine, Hospital Tengku Ampuan Afzan, Jalan Tanah Putih, 25100 Kuantan, Pahang.

<sup>2</sup> Department of Internal Medicine, Sultan Ahmad Shah Medical Centre @ International Islamic University Malaysia, Jalan Sultan Haji Ahmad Shah, Bandar Indera Mahkota, 25200 Kuantan, Pahang.

### ABSTRACT

Madam S, who diagnosed to have stage IV lung adenocarcinoma with exon 21 L858R point mutation (T3N2M1a) was admitted for massive pericardial effusion in April 2016. She was ECOG 4 on admission. Her ECOG improved to 1 after pericardial tapping and initiation of free sample erlotinib 100 mg daily. Repeated CT thorax post treatment showed the disease was partially responded. Due to financial constraints, she had never bought any EGFR-TKI. She was given a free sample of erlotinib intermittently for total of 12 months followed by intermittent afatinib supply for 2 years. Due to this limited supply, she took half doses of afatinib by cutting a 40 mg tablet once every few days to sustain the continuation of cancer treatment. No major side effects were observed and she remained ECOG 0 with good weight gain. Up to her last clinic visit in September 2021, her PFS was more than 5 years. Intermittent doses of EGFR-TKI may prolong PFS in patients with advanced EGFRm+ NSCLC who has limited treatment options.

*Malaysian Journal of Medicine and Health Sciences* (2023) 19(2):341-343. doi:10.47836/mjmhs19.2.48

**Keywords:** Epidermal growth factor receptor, Cancer, Non-small cell lung adenocarcinoma, Resistant, Tyrosine kinase inhibitor

### Corresponding Author:

Tan Sin Nee, MRCP

Email: christine0507@live.com

Tel: +609-5133333

### INTRODUCTION

Epidermal growth factor receptor tyrosine kinase inhibitor (EGFR-TKI) is widely recognized as the first-line treatment for non-small cell lung cancer (NSCLC) with sensitizing EGFR mutations (EGFRm+). Extensive studies had proven that EGFR-TKI provides better progression free survival (PFS) comparing to standard chemotherapy. However, there is no randomized controlled study of EGFR-TKI use in patients with poor Eastern Cooperative Oncology Group (ECOG) harboring an EGFRm+. In developing countries like Malaysia, EGFR-TKI is considering an expensive treatment and is not freely available in the public hospital setting. Therefore, some patients prefer to take half of the recommended dose (half tablet) to allow more sustainable medication supply and perhaps better tolerability. This case presents a patient with advanced EGFRm+ NSCLC and poor ECOG, had a durable response toward intermittent doses of EGFR-TKI.

### CASE REPORT

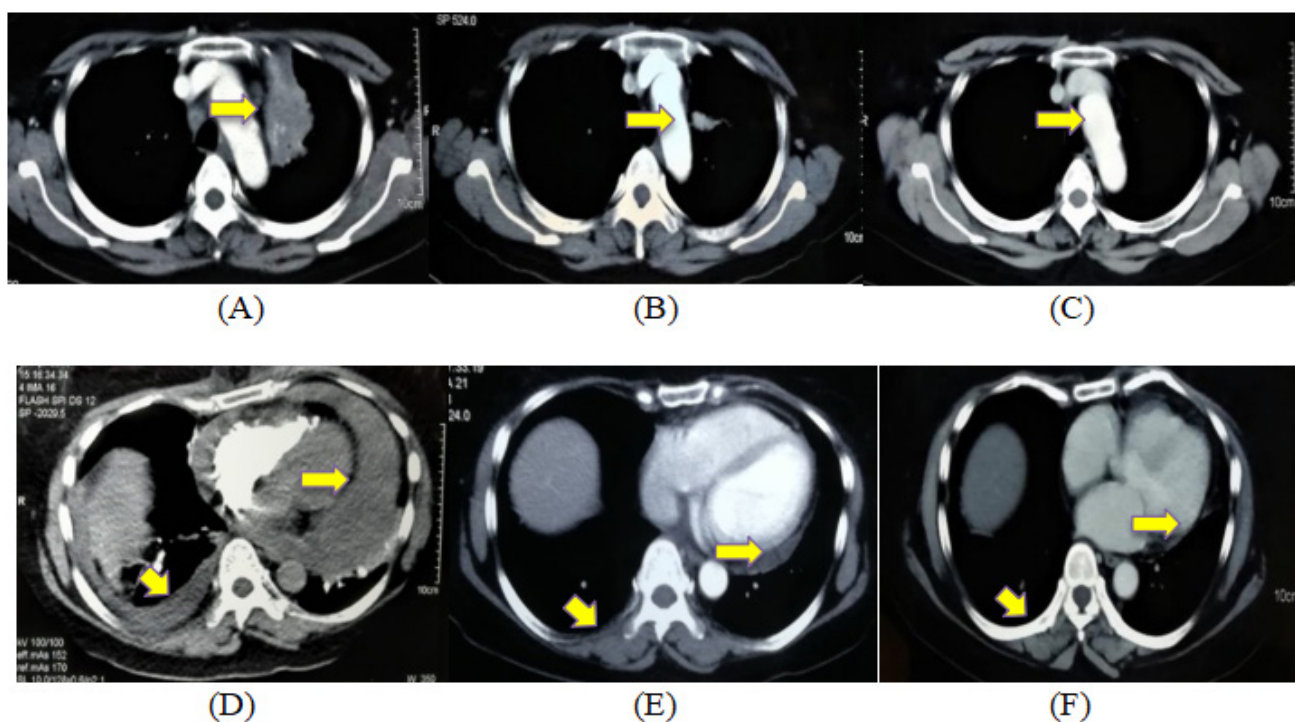
Madam S, a 61-year-old housewife, non-smoker, was presented with 4-months history of cough and constitutional symptoms. The patient was ECOG 1 during first clinic encounter in March 2016. Computed tomography (CT) thorax showed left upper lobe lung mass (Fig. 1A). A bronchoscopy was performed. While awaiting biopsy result, she developed acute shortness of breath, necessitating an emergency hospital admission in April 2016. CT pulmonary angiogram revealed the presence of a massive pericardial effusion and right pleural effusion (Fig. 1D). A Cook catheter was inserted and a total of 1.65 L of hemorrhagic fluid was drained. She was diagnosed to have stage IV lung adenocarcinoma with exon 21 L858R point mutation (T3N2M1a). She was offered free EGFR-TKI treatment because of poor socioeconomic support and functional status deemed not suitable for chemotherapy. After initiation of erlotinib, pleural and pericardial tapping were performed, she was discharged well. She remained ECOG 1 upon clinic follow up 2 weeks post discharge. The repeated CT thorax revealed 70% tumour regression with resolving pericardial effusion and right pleural effusion indicating the disease was partially responded

(Fig. 1B & 1E). She experienced grade 1 paronychia and mild diarrhea during the treatment. EGFR-TKI was continued for 6 months with welfare department support. While waiting for re-supply of EGFR-TKI, she was given 2 cycles of chemotherapy (cipplastin and gemcitabine). Erlotinib was restarted in December 2016 with 6 months' supply by National Cancer Council Malaysia. The patient was never able to afford any EGFR-TKI. Hence, she was treatment free for 2-months when the free supply was cut-off. Her disease was remained stable with quarterly CT scan follow up. Fortunately, she has received a free sample of afatinib from July 2017–July 2019 on an availability basis. She was first started with half a tablet of 40 mg afatinib for 2-months followed by every alternate day for 2-months and subsequently once every 3 days due to limited supply. CT thorax in May 2019 revealed stable disease with no significant interval changes (Fig. 1C & 1F). She has good weight gain and remained ECOG 0 during the last clinic review in early September 2021.

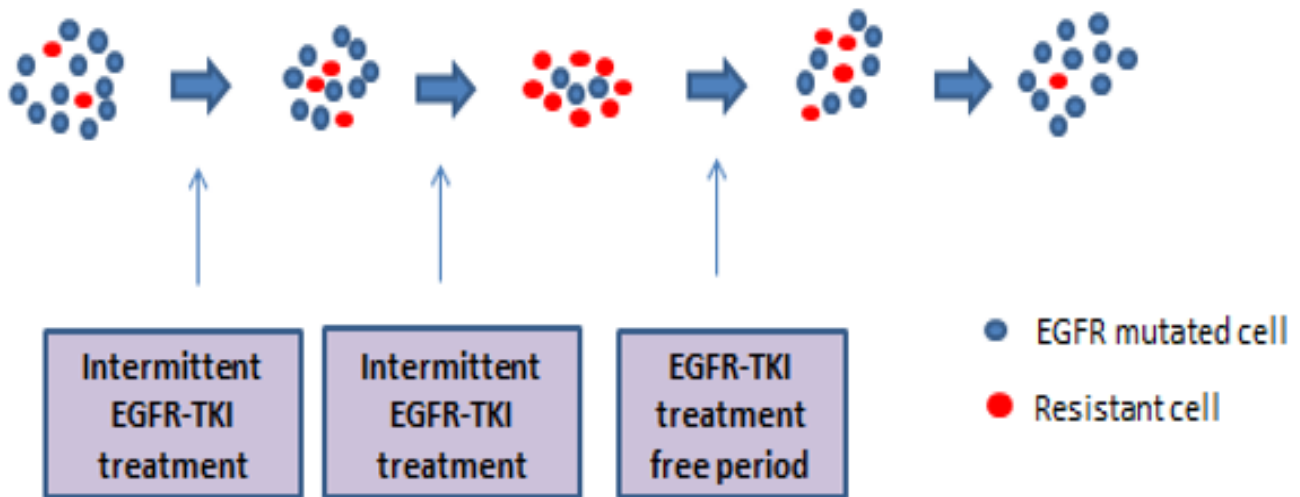
**DISCUSSION**

EGFR-TKI has evolved since its introduction in 2002. Most phase III randomized controlled trials on EGFR-TKI only enrolled patients with good functional performance status. However, EGFR-TKI has shown dramatic benefits in response rates and improves functional performance status in real-world practice. In Malaysia, EGFR-TKI treatment is deemed to be a luxury treatment because it costs about USD 1000/month. While Basic Amenities

Survey 2016 showed the median monthly household income in Malaysia for a low socioeconomic group was USD 750/month. Hence, the idea of intermittent low dose EGFR-TKI treatment emerged. The rationales were, firstly, for the patient with low socioeconomic status, a box of 40 mg afatinib can be taken for 2-months duration (half tablet). Secondly, lung cancer is considered as highly heterogeneous as they contain resistant cells due to genetic and environmentally mediated mechanisms. The characteristic of high heterogeneity leading the metastatic lung cancer remained fatal despite the advancement of lung cancer treatment. No one size-fits-all strategy along the metastatic lung cancer treatment journey. Hence, adaptive cancer therapy has been described (Figure 2). Improvising the conventional therapies by dose modulation tumour control with less drug, or a vacation-oriented schedule may have prolonged PFS and reduce resistance and recurrence.<sup>1</sup> Thirdly, low dose EGFR-TKI has better tolerance hence improved patient adherence. A post-hoc analysis reported dose reductions due to drug side effects in 53.3% and 28% of patients in LUX-Lung 3 and 6 trials respectively.<sup>2</sup> Two real-world studies reported dose reduction of afatinib has no impact on median PFS and overall survival.<sup>3,4</sup> Moreover, a meta-analysis have shown that patients with EGFRm+ NSCLC exon 21 L858R tend to have lower response rate, shorter PFS and OS comparing to those with exon 19 deletion mutation in response to EGFR-TKI therapy.<sup>5</sup> Our case report demonstrated an advanced EGFRm+ NSCLC with exon 21 L858R point mutation treated with intermittent low



**Figure 1:** (From left to right): CT thorax revealed left upper lobe lung mass with maximum diameter of 55 mm with paraaortic and subcarinal lymph nodes (A) in January 2016. CT thorax upon hospitalization in April 2016 showed right pleural effusion and massive pericardial effusion 56 mm (D). CT thorax one-month post EGFR-TKI commencement revealed 15 mm left lung mass (B) and resolving pericardial effusion and right pleural effusion (E) in May 2016. Latest CT thorax showed less than 10 mm left lung mass (C) and complete resolution of pericardial and pleural effusion in May 2019.



**Figure 2:** EGFR mutated cells will be suppressed after initiation of EGFR-TKI treatment while the resistant cancer cells will over-grow. When the treatment is ceased, the mutated cells will re-grow and suppress the resistant cells.

dose EGFR-TKI therapy had successfully prolonged PFS for more than 5 years duration in patient with financial constraints or limited treatment options. This case is consistent with results from the LUX-Lung and real-world studies, showing that dose adjustment of afatinib did not compromise its clinical efficacy with better tolerance. Large scale study is encouraged to further look into intermittent low dose treatment regime in treating EGFRm+ NSCLC in center with limited resources or treatment options.

## CONCLUSION

Intermittent doses of EGFR-TKI may prolong PFS in patients with advanced EGFRm+ NSCLC who has limited treatment options.

## ACKNOWLEDGEMENT

Appropriate written informed consent was obtained for publication of this case report and accompanying images.

## REFERENCES

- Gallaher JA, Enriquez-Navas PM, Luddy KA, Gatenby RA, Anderson ARA. Spatial Heterogeneity and Evolutionary Dynamics Modulate Time to Recurrence in Continuous and Adaptive Cancer Therapies. *Cancer Res.* 2018 Apr 15;78(8):2127-2139. doi: 10.1158/0008-5472.CAN-17-2649.
- Yang JC, Sequist LV, Zhou C, Schuler M, Geater SL, Mok T, et al. Effect of dose adjustment on the safety and efficacy of afatinib for EGFR mutation-positive lung adenocarcinoma: post hoc analyses of the randomized LUX-Lung 3 and 6 trials. *Ann Oncol.* 2016 Nov;27(11):2103-2110. doi: 10.1093/annonc/mdw322.
- Tanaka H, Taima K, Itoga M, Ishioka Y, Baba K, Shiratori T, et al. Real-world study of afatinib in first-line or re-challenge settings for patients with EGFR mutant non-small cell lung cancer. *Med Oncol.* 2019 May 14;36(6):57. doi: 10.1007/s12032-019-1278-9.
- Halmos B, Tan EH, Soo RA, Cadranet J, Lee MK, Foucher P, et al. Impact of afatinib dose modification on safety and effectiveness in patients with EGFR mutation-positive advanced NSCLC: Results from a global real-world study (RealGiDo). *Lung Cancer.* 2019 Jan;127:103-111. doi: 10.1016/j.lungcan.2018.10.028.
- Sheng M, Wang F, Zhao Y, Li S, Wang X, Shou T, et al. Comparison of clinical outcomes of patients with non-small-cell lung cancer harbouring epidermal growth factor receptor exon 19 or exon 21 mutations after tyrosine kinase inhibitors treatment: a meta-analysis. *Eur J Clin Pharmacol.* 2016 Jan;72(1):1-11. doi: 10.1007/s00228-015-1966-0.