

## CASE REPORT

# Irreparable Massive Rotator Cuff Tear in a Young Patient With Recurrent Anterior Shoulder Dislocation

Raymond DK Yeak<sup>1</sup>, Peter T Campbell<sup>2</sup>

<sup>1</sup> Department of Orthopaedic Surgery, Faculty of Medicine and Health Sciences, Universiti Putra Malaysia, 43400 Serdang, Selangor, Malaysia

<sup>2</sup> Western Orthopaedic Clinic, Subiaco, Perth, WA, Australia

### ABSTRACT

Combined latissimus dorsi transfer, subscapularis repair and Latarjet surgery is rare and has never been reported. A 35-year-old man with chronic shoulder pain had a long history of instability of his right shoulder. The first episode occurred during a game of touch rugby followed by multiple episodes of subluxation. MRI was done which showed complete tear of the subscapularis anteriorly which was retracted and atrophied indicating a longstanding tear. There was also significant mid substance supraspinatus tendon tear. Patient then underwent two surgeries. The initial surgery found the rotator cuff to be irreparable with glenoid bone loss and only acromioplasty with acromioclavicular joint resection were performed. He then had a single stage surgery consisting of latissimus dorsi transfer, Latarjet procedure and subscapularis repair. A two-stage surgery can be avoided, and good results can be obtained provided that the patient undergo correct rehabilitation regime after undergoing a single stage surgery.

**Keywords:** Latarjet, Rotator cuff tear, Shoulder dislocation, Tendon transfer, Latissimus dorsi

### Corresponding Author:

Raymond DK Yeak, MRCS (Edin)

Email: rayyeak.dk@upm.edu.my

Tel: +603-9769 2637

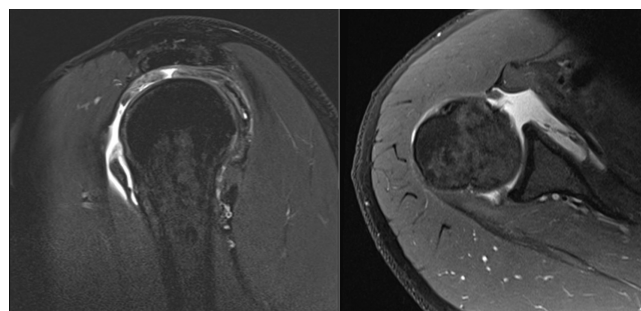
### INTRODUCTION

Combined latissimus dorsi transfer as well as subscapularis repair and Latarjet procedure is rare and has never been reported. To date, there have been few researches that offers guidance in the management of combined instability with rotator cuff tear. The rehabilitation regime differs for a latissimus dorsi tendon transfer and a Latarjet surgery. Therefore, a single stage surgery requires the appropriate patient selection and surgical indication with the correct rehabilitation regime.

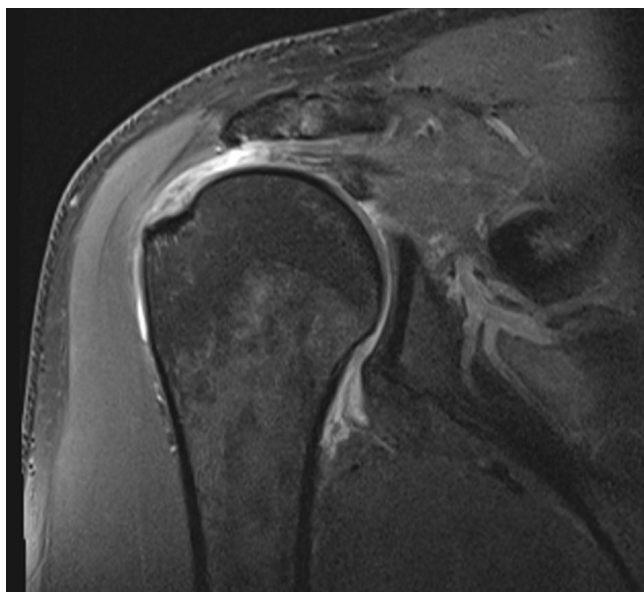
### CASE REPORT

A 35-year-old man with chronic shoulder pain had a long history of instability in his right shoulder. The first episode occurred during a game of touch rugby followed by multiple episodes of subluxation. Pre-operative, patient had recurrent episodes of shoulder dislocation. The anterior apprehension and anterior drawer test were positive. There was a decrease in internal rotation strength with positive Belly press and Bear Hug tests. He also had a positive Jobe test and decreased strength in the external rotation resistance of the elbow at the side. He had magnetic resonance imaging (MRI) done

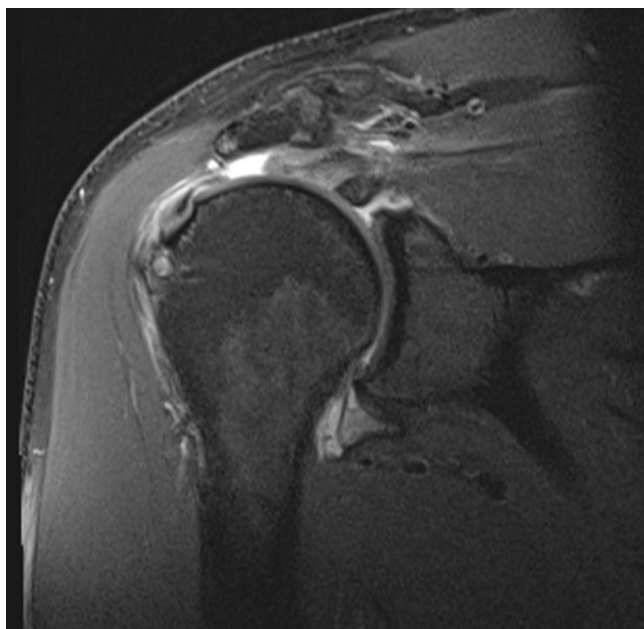
which showed complete tear of the subscapularis anteriorly which was retracted and atrophied indicating a longstanding tear (Fig 1). He also had significant mid substance tear of the supraspinatus tendon (Fig 2) and infraspinatus tendon (Fig 3) as well. He was planned for a combined subacromial decompression and rotator cuff repair of the rotator cuff and a Latarjet procedure to confer stability to his shoulder joint. Arthroscopic assessment of the patient's right glenohumeral joint showed that he had complete loss of the entire subscapularis, supraspinatus and most of the infraspinatus. The joint itself was well preserved and there had been previous rupture of the long head of biceps tendon. The glenoid bone loss was measured arthroscopically with a probe. It was used to measure the distance from the bare spot center to the inferior glenoid rim and the glenoid bone loss was found to be more than 20%. He also had a stable meso-type



**Figure 1: Preoperative magnetic resonance imaging showing subscapularis tear [left (sagittal view) and right (axial view)]**



**Figure 2: Preoperative magnetic resonance imaging showing supraspinatus tear (coronal view)**

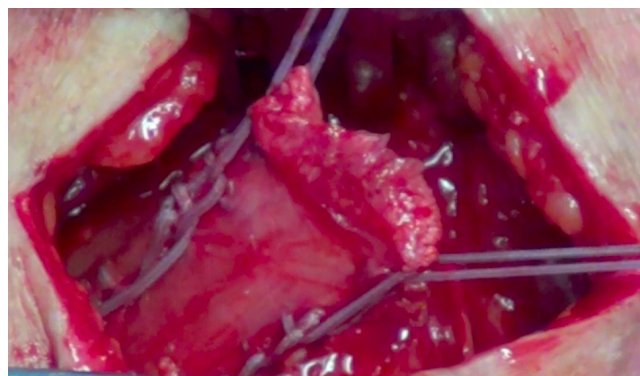


**Figure 3: Preoperative magnetic resonance imaging showing infraspinatus tear (coronal view)**

os acromiale. An acromioplasty and acromioclavicular joint resection were performed via a lateral portal splitting approach. The rotator cuff was mobilised but could not be brought back to the articular margin. This patient had an irreparable rotator cuff tear. The patient was then planned for a latissimus tendon transfer. Latissimus tendon transfer was the preferred technique for younger patients with massive irreparable cuff tears without arthropathy. The patient was then planned for a staged procedure by performing a latissimus tendon transfer followed by a Latarjet procedure. However, after further discussion with the patient, we had opted to proceed with a single stage procedure. Computed tomography scan was not performed as the arthroscopic

assessment of the patient's right glenohumeral joint and the glenoid bone defect had already been done prior to embarking on the combined tendon transfer and the Latarjet procedure.

Five months after the index surgery, the patient had the single stage surgery consisting of latissimus dorsi transfer, Latarjet procedure and subscapularis repair. The latissimus dorsi tendon was identified in the posterior axilla and traced back to its insertion on the proximal humerus via a posterior axillary approach. The tendon was dissected from the humerus and the musculotendinous unit mobilised to the neurovascular pedicle. This was passed superiorly in the plane initially between the teres major and the posterior deltoid and the humeral shaft and the long head of triceps. An incision through the previous lateral scar was performed and the tendon delivered to the tuberosity (Fig 4). The tendon was attached utilising two intraosseous anchors anterior to the midline and superiorly. Both wounds were closed in layers. A third incision through an anterior deltopectoral approach was performed. The coracoid process was osteotomised at its base. There was also gross insufficiency of the subscapularis with the entire superior half missing and the inferior half torn and retracted. The remnants of the capsulolabral complex were repaired to the articular margin utilising two intraosseous anchors and the coracoid process screwed into the anterior glenoid rim utilising a screw and washer. The lower half of subscapularis was mobilised and repaired to the lesser tuberosity with an intraosseous anchor. All wounds were closed in layers.



**Figure 4: The tendon delivered to the tuberosity and was attached utilising two intraosseous anchors**

He was put in a sling for six weeks and was mobilised according to our regime. For the first 3 weeks, active range of motion (AROM) exercises was started for the elbow, wrist and neck with no shoulder external rotation beyond neutral and no resisted shoulder internal rotation. From the 3rd till the 6th week, shoulder flexion and abduction passive range of motion (PROM) exercises were performed as tolerated. From the 6th week onwards, PROM, AROM and active assisted range of motion (AAROM) exercises were performed in all planes of movement as tolerated. At post-operative

3 months, the anterior apprehension test was negative with a negative Belly press, Bear Hug, and Jobe tests. He continued with AAROM exercises as well as gentle stretches, light band work and pool-based rehab programme to regain range of motion. He avoided any formal strength training for 4 months. The patient has since regained his full range of motion with very good shoulder function. There was resolution of the chronic shoulder pain and his instability symptoms with no more recurrence at the one-year follow-up. However, he had not regained his full strength which could be due to the presence of subscapularis tear.

## DISCUSSION

Latissimus dorsi tendon transfer restores shoulder function and active shoulder external rotation in irreparable rotator cuff tears. (1) Rotator cuff tear in association with shoulder dislocation is common in older patients. Neviasser et al reported 86% of his patients had rotator cuff tear with initial dislocation in patients over 40 years old. (2) However, it was uncommon for the younger patients to have such an injury and it was usually traumatic in nature. (3) This correlated with our case which occurred after touch rugby. Latarjet procedure was performed in our case as the patient was a contact athlete with history of recurrent shoulder dislocation and glenoid bone loss. Krishnan et al found excellent results for arthroscopic rotator cuff repair with and without concomitant procedures when performed in patients younger than the age of 40. (3). In our case, our patient had the advantage of age, being a younger patient. Weening et al reported poor outcome when latissimus dorsi tendon transfer was performed with subscapularis tear. (4) However, we did not encounter this issue with our case. A study by Iannotti et al reported good outcomes when the partial upper subscapularis tear could be repaired. (5). This correlated with our patient as we managed to repair the subscapularis tear partially. However, the patient had a strength deficit and he was not able to recover from it in which he was already informed pre-operatively. This was not a problem as he was satisfied with the pain relief and the resolution of his instability symptoms. Weening et al reported that this may be due to the inability of LD to center the humeral

head (4).

## CONCLUSION

With the appropriate patient selection and surgical indication, the patient was able to get full range of motion with no pain and instability. Combined procedures of latissimus dorsi transfer as well as subscapularis repair and Latarjet procedure was possible with the correct rehabilitation regime and patient was able to return to play. Despite its rarity, we should always be aware of the possibility of rotator cuff tear in a young patient with recurrent anterior shoulder dislocation. Good results can be obtained with a single stage procedure thereby avoiding the need for an additional surgery.

## ACKNOWLEDGEMENTS

We wish to acknowledge the patient for his consent for the publication of this case report and any accompanying images.

## REFERENCES

1. Gerber C, Vinh TS, Hertel R, Hess CW. Latissimus dorsi transfer for the treatment of massive tears of the rotator cuff: A preliminary report. *Clin Orthop*. 1988;232:5161.
2. Neviasser R, et al. Anterior Dislocation of the Shoulder and Rotator Cuff Rupture. *Clinical Orthopaedics*. 1993;291
3. Krishnan SG, Harkins DC, Schiffert SC, Pennington SD, Burkhead WZ. Arthroscopic repair of full-thickness tears of the rotator cuff in patients younger than 40 years. *Arthroscopy*. 2008;24:324-328
4. Weening A.A., Willems W.J. Latissimus dorsi transfer for treatment of irreparable rotator cuff tears. *Int. Orthop*. 2010;34(8):1239-1244
5. Iannotti J.P., Hennigan S., Herzog R., Kella S., Kelley M., Leggin B., Williams G.R. Latissimus dorsi tendon transfer for irreparable posterosuperior rotator cuff tears. Factors affecting outcome. *J. Bone Joint Surg. Am*. 2006;88(2):342-348.