

ORIGINAL ARTICLE

Effects of Tualang Honey on Pain Behaviour and Oxidative Stress in the Thalamus of Prenatally Stressed Rat Offspring

Hidani Hasim¹, Che Badariah Abd Aziz¹, Siti Qusyasyiah Ahmad Suhaimi¹, Mahaneem Mohamed¹, Idris Long², Rahimah Zakaria¹

¹ Department of Physiology, School of Medical Sciences, Health Campus, Universiti Sains Malaysia, 16150 Kubang Kerian, Kelantan, Malaysia

² School of Health Sciences, Health Campus, Universiti Sains Malaysia, 16150 Kubang Kerian, Kelantan, Malaysia

ABSTRACT

Introduction: Increased nociceptive responses were shown in the offspring of prenatally stressed rats. Reports have demonstrated the anti-nociceptive effects of Tualang honey in the rat offspring. The present study was done to determine whether the modulation of nociceptive behaviour by Tualang honey was mediated by modulating changes in the histology, oxidative stress parameters and N-methyl-D-aspartate (NMDA) receptors in the thalamus of the rat offspring. **Methods:** Eighteen Sprague Dawley pregnant rats were randomly assigned to control (C), stress (S) and stress-treated with Tualang honey (SH) groups. Stress was given in a form of restraint stress. Tualang honey was given to SH group from first day of pregnancy until delivery. Thirty-three adult male offspring were subjected to formalin test before they were sacrificed. Nociceptive behaviour score, number of neurons, level of oxidative stress parameters and NMDA receptors in the thalamus were analysed by using one-way ANOVA. **Results:** The study demonstrated a significant decrease in mean nociceptive behaviour score ($p < 0.05$) with lower malondialdehyde (MDA, $p < 0.05$) and higher superoxide dismutase SOD and catalase levels in the thalamus of SH group compared to S group ($p < 0.05$). There was also increased Nissl positive neurons in the thalamus of SH group compared to S group. There was no significant difference in NMDA receptor level between S and SH groups. **Conclusion:** The modulation of nociceptive responses in the prenatally stressed rat offspring by Tualang honey was associated with improvement in oxidative stress parameters and histology of the thalamus in the rat offspring exposed to prenatal stress.

Keywords: Tualang honey, Prenatal stress, Nociceptive behaviour, Oxidative stress, Thalamus

Corresponding Author:

Che Badariah Abd Aziz, PhD
Email: badariah@usm.my
Tel: +609-7676162

INTRODUCTION

It is estimated that up to 20% of women experience stress and depression during pregnancy (1). Reports have shown that prenatal stress may result in pregnancy complications and disturbance in offspring development and behaviour (2-5). Studies have reported that prenatal stress is associated with changes in nociceptive responses in rat and human offspring (6-8). The responsible mechanism that leads to the abnormalities may be related to stress-induced rise of glucocorticoid hormone in the offspring. The high glucocorticoid level may contribute to increased oxidants level and impaired development of the foetal brain (9, 10). The brain is vulnerable to oxidative injury and has a comparatively modest antioxidant defence (11). The high amount of free radicals in the brain leads to an imbalance between production and elimination of free radicals which result in oxidative stress (10, 12)].

One of the mechanisms for the increased in oxidative stress is believed to be due to calcium dysregulation as a result of N-methyl-D-aspartate (NMDA) receptor hyperactivity which leads to neurotoxicity (13). Previous studies have shown the effects of prenatal stress on various parts of the brain including cerebral cortex, cerebellum, hippocampus, hypothalamus, and amygdala but the effects on the thalamus have not been reported yet (12, 14-16). The thalamus is a crucial relay station for transmitting nociceptive information to the cerebral cortex. There is a large amount of evidence that showed the important role of thalamus in nociceptive responses in acute inflammatory and neuropathic pain models (17-21). In addition, it has been shown that NMDA receptors in the thalamus have important role in the development and maintenance of hyperalgesia in acute inflammatory pain (19). Whether thalamus is involved in modulating the nociceptive responses in the offspring following prenatal stress needs to be investigated.

Available evidence suggests that Tualang honey that contains antioxidant has antinociceptive effects when administered directly to adult rats (22, 23). Tualang honey is a natural product consisting of variable compositions

such as catechin, gallic acid, benzoic acid and trans-Cinnamic acid (24). These variances based on floral sources, geographical origin, total phenolic content, water proportion and colour (25, 26). Previously, it has been extensively studied for the treatment of various medical conditions and has been found to have therapeutic activities including antibacterial, anti-inflammatory and anticancer properties (27-29).

Tualang honey administration to a group of stressed pregnant dams was associated with reduced nociceptive behaviour of the offspring compared to the offspring from the untreated stress group (6). The present work is part of a larger study looking at the effects of prenatal stress on pain modulating structures in the central nervous system including the spinal cord (30). The exact mechanisms on how Tualang honey prevent the modulation of nociceptive responses at the level of the thalamus in the prenatally stressed rat offspring are not much known. Therefore, this study was conducted to determine whether modulation of nociceptive responses following administration of Tualang honey was associated with changes in the histology, oxidative stress and alteration of NMDA receptor level in the thalamus of rat offspring exposed to prenatal stress.

MATERIALS AND METHODS

Animals

Eighteen adult female Sprague-Dawley rats (6 to 8 weeks old) were obtained from the Animal Research and Services Centre (ARASC), Universiti Sains Malaysia (USM). All rats were acclimatised for 3-5 days with ad libitum access to water and standard chow, maintained on a 12 h light/dark and controlled temperature ($\pm 23^{\circ}\text{C}$). All procedures were performed in accordance with the guidelines approved by the Animal Ethics Committee of Universiti Sains Malaysia (USM/Animal Ethics Approval/2014(94)(577)).

Experimental groups

Each female rat at proestrus was caged with a proven fertile male rat. Vagina smear was done the next morning between 0900 and 1000 hours and sperm positive smear was considered as day 0 of pregnancy (31). Sperm positive smear confirmed that mating has occurred and the rat was observed for sign of pregnancy. If there was failure of pregnancy, these rats would be excluded from the study. These pregnant dams were kept in a standardised individual cage and were randomly divided into three groups ($n=6$ for each group); control (C), stress (S) and stress-treated with Tualang honey (SH). Tualang honey (Federal Agricultural Marketing Authority, Malaysia) at 1.2g/kg was given once daily via oral gavage from day one of pregnancy until delivery (6). At the dose given, Tualang honey may require around 10 days before its effects were fully seen, thus protected the developing brain during prenatal stress (32, 33). C and S groups were given distilled water instead of Tualang

honey. Following the delivery of the pups, the male rat offspring were weaned at postnatal day 21. One or two of male pups delivered from each dam of each group were randomly taken for evaluation in this study. They were housed according to their respective groups until 10 weeks of age. Female rats were not included because they had variation in nociceptive sensitivity throughout oestrus cycle (34).

Maternal Stress Model

Repeated restraint was used as a model of maternal stress starting from day 11 of pregnancy until delivery (31). This period was chosen because brain development in rats occurs between rat embryonic day 11 to day 21 (33). The corresponding pregnant dams were restrained thrice daily for 30 minutes by placing the animal in a plastic cylinder measuring 23 cm x 6 cm (6). This method was chosen because it was shown to be associated with increased stress hormone level (corticosterone), produced pregnancy complications and increased in nociceptive behaviour in the rats' offspring (6, 35).

Formalin Test

A total number of 33 male rats' offspring, 10 weeks of age, were used in this experiment ($n=11$ per group). Each rat was placed in the testing chamber for 15 to 30 minutes to allow acclimatisation before the formalin injection. The plantar surface of right hind paw was injected subcutaneously with 50 μl of 1% formalin and each rat was placed in an observation chamber measuring 26 cm x 20 cm x 20 cm with a mirror mounted at 45° below it, permitting unhindered observation of the rat's paw (6). The rat's nociceptive behaviour was recorded with a video camera for one hour from the time of injection. The recording was analysed by two observers blinded to the treatment of each rat and the formalin test score was tabulated every minute. The quantification was based on the test score (0 to 3) in the behavioural categories described by Dubuisson and Dennis (30, 36). Behaviour score was tabulated every minute and averaged at 5-minute intervals. Nociceptive behavioural score was given from 0 to 3 (no pain to severe pain). Zero (0) was given when the injected paw was not favoured (no pain); 1= injected paw has little or no weight on it (mild pain); 2= injected paw was elevated (moderate pain), and 3 = the injected paw was licked, bitten or shaken (severe pain).

Sacrifice of Animals

Two hours post formalin injection, rats were euthanized with an overdose of sodium pentobarbital (Nembutal; 100 mg/kg body weight, i.p.) and their brains were removed to assess the histology, oxidative stress parameters and NMDA receptors in the thalamus.

Histology of ventral posterolateral thalamic nucleus (VPL)

The thalamus was fixed in 10% formalin solution and dehydrated in an automated tissue processor machine

(Leica TP1020, Germany). After the dehydration process, the samples were blocked with paraffin wax and kept in -4°C until further process. Coronal brain sections were trimmed to $5\ \mu\text{m}$ using microtome blade (low profile, PTFE coated microtome blade, Duraedge, USA). The thalamus sections were taken from bregma $-4.44\ \text{mm}$ to $-2.16\ \text{mm}$ at a regular space interval of $100\ \mu\text{m}$ (37). The tissues were then mounted on glass slides (Sail Brand, China), air dried and kept at 37°C . Nissl staining was performed according to the standard procedure. For each section, number of Nissl-positive cells was counted by taking the mean of four fields in VPL area. VPL was chosen because the receptive field for the hindpaw is located in the region (17). Only the optimally visualised Nissl stained cells in one focal plane were counted to prevent double counting of neurons with abnormal shapes. Nissl stained neurons were distinguished from non-neuronal cells by their round shape, prominent nucleolus and presence of Nissl substances in the cytoplasm. Abnormal neurons were characterised by reduced staining intensity of Nissl substances and presence of dark neurons.

Assay procedures for oxidative stress parameters

Homogenate (10% w/v) was made from the thalamus portion of the brain in ice-cold 0.1 M phosphate-buffered saline (PBS, pH 7.4). The homogenates were centrifuged ($10,000 \times g$) for 10 minutes and supernatant were kept at -80°C until assay. The levels of malondialdehyde (MDA), superoxide dismutase (SOD) and catalase (CAT) activity were measured by using competitive enzyme-linked immunosorbent assay kits (USCN Life Science Inc., Wuhan, China).

Assay procedures for N-methy-D-aspartate (NMDA) receptors

The tissue was homogenized and the sample was centrifuged for 20 minutes at speed of 2000-3000 rpm. Supernatant was collected and stored at -80°C until assay. The assay was conducted using reagent kit supplied by USCNK (Qayee-Bio, Shanghai, China). The kit used a double antibody sandwich enzyme-linked immunosorbent one-step process to assay the level of NMDA receptors in the sample.

Statistical Analysis

SPSS version 22 software was used to analyse the data in the study. Numerical data were analysed by descriptive statistics. The data distribution were initially determined whether it was normally distributed or not by the test of normality. Behavioural data were assessed using repeated measure ANOVA followed by post-hoc analysis (Tukey test). Oxidative stress parameters, number of Nissl stained neurons, and NMDA receptor level were analysed by using one-way ANOVA followed by Bonferroni test for post-hoc comparisons. Level of significance was set at $p < 0.05$. Results are expressed as mean \pm standard error mean (SEM).

RESULTS

Mean Nociceptive Behaviour Score

The formalin test showed increased nociceptive response in the first five minutes post-formalin injection (phase 1). It was followed by reduced nociceptive behaviour score between minutes 5 to 10 and in phase 2 of formalin test, there was increased nociceptive behaviour response between minutes 15 to 30. In the later part of phase 2, there was a gradual decrease in the score (Figure 1).

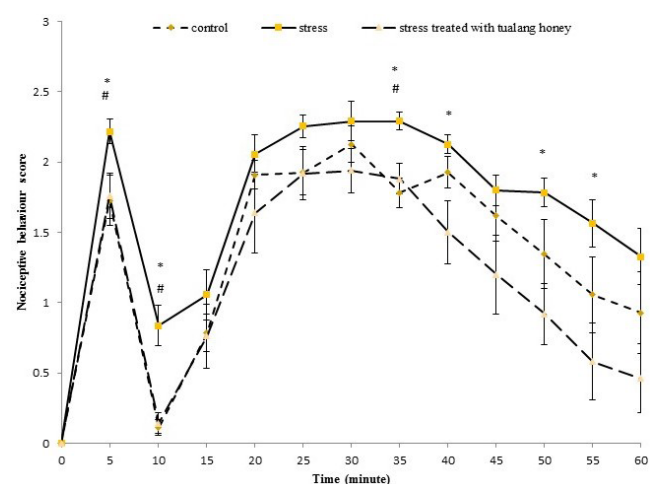


Figure 1: Nociceptive behaviour score from formalin test among the groups (n=11). Data are presented as mean \pm SEM. # $P < 0.05$ statistical comparison between control and stress groups. * $P < 0.05$ statistical comparison between stress and stress treated with Tualang honey groups.

There was a significant difference in nociceptive behaviour score between the groups ($F(\text{df}) = 8.593(2,29)$, $p\text{-value} < 0.001$). The nociceptive behaviour score from the stress group was significantly higher compared to control group at minute 5, 10 and 35 ($p < 0.05$). The score was also significantly higher in stress group when compared with stress-treated with Tualang honey groups at minute 5, 10, 35, 40, 50 and 55 ($p < 0.05$). Statistical comparison between control group and stress-treated with Tualang honey group revealed no significance difference.

Number of Nissl-positive neurons in ventral posterolateral nucleus of thalamus (VPL)

There was a significant difference in the mean number of Nissl positive neurons in the VPL of the offspring between all groups ($F(2,17) = 7.304$, $p < 0.05$) (Table 1). The analysis by post-hoc Bonferroni test showed a significant decrease in number of Nissl-positive neurons ($p < 0.05$) in stress group compared to control group. Additionally, the number of Nissl-positive neuron in stress-treated with Tualang honey group was significantly higher ($p < 0.05$) than stress group. However, there was no significant difference ($p = 1.000$) between control and stress-treated with Tualang honey group (Table 1).

Table I: Number of Nissl positive neurons in the left ventral posterolateral region

Group	Mean ± SEM
Control	29.18 ± 1.27
Stress	22.45 ± 1.91*
Stress treated with Tualang honey	30.56 ± 1.54#

One way ANOVA between groups analysis was applied followed by post-hoc multiple comparisons using Bonferroni method.
 *P<0.05 statistical comparison between control and stress groups
 #P<0.05 statistical comparison between stress and stress treated with Tualang honey groups

Histology of ventral posterolateral thalamic nucleus (VPL)

The normal histology of VPL was observed in the control group. There were abundant healthy neurons. The architecture was preserved and Nissl substances in the cytoplasm were clearly visible in Figure 2. Similar features were observed in the VPL of the offspring from stress-treated with Tualang honey group. In stress-treated group, the neuron number was preserved with normal architectures and arrangement of neurons in Figure 2. In contrast, the neuronal density of VPL in the stress group was reduced. The neurons were shrunken and sparse meanwhile the intensity of cytoplasmic staining was reduced (Figure 2). There was significant neuronal loss with existences of dark neurons that suggests neuronal damage.

Oxidative Stress Parameters

The results showed a significant increase in MDA level in the thalamus of the offspring from stress group compared to C group (p < 0.001). Remarkably, there was a significant decrease (p < 0.05) in the MDA level in SH

group compared to S group as determined by one-way ANOVA (Table 2). Meanwhile, the level of MDA showed no significant difference between SH and C groups (P = 0.083). In addition, there was a marked decrease in CAT and SOD activity (p < 0.05) in S group compared to C groups. The difference was only significant for SOD activity but not for CAT. Both of the antioxidants activity, SOD and CAT, were significantly higher in SH group compared to S group (p<0.05) (Table II).

Table II: Level of oxidative stress parameters in the control, stress and stress treated groups

	MDA (ng/ml)	CAT (ng/ml)	SOD (pg/ml)
Control	15.09 ± 0.28	4.67 ± 0.18	4751.25 ± 188.26
Stress	17.49 ± 0.38***	4.20 ± 0.19	3757.63 ± 124.54*
Stress treated with Tualang honey	16.20 ± 0.71#	5.13 ± 0.16*	4879.38 ± 238.78#

One way ANOVA between groups analysis was applied followed by post-hoc multiple comparisons using Bonferroni method.
 ***P<0.001 statistical comparison between control and stress groups
 *P<0.05 statistical comparison between control and stress groups
 #P<0.05 statistical comparison between stress and stress treated with Tualang honey groups

Level of NMDA receptors

There was a significant difference in mean of NMDA receptor level between all groups (F(2,18) = 4.334, p<0.05). The analysis by post-hoc Bonferroni test showed that the NMDA receptor level in the thalamus of the offspring from S group was significantly higher (p<0.05) compared to C group (Table III). However, the differences were not significant when compared between SH and S (p=0.343) and between SH and C groups (p=0.654)

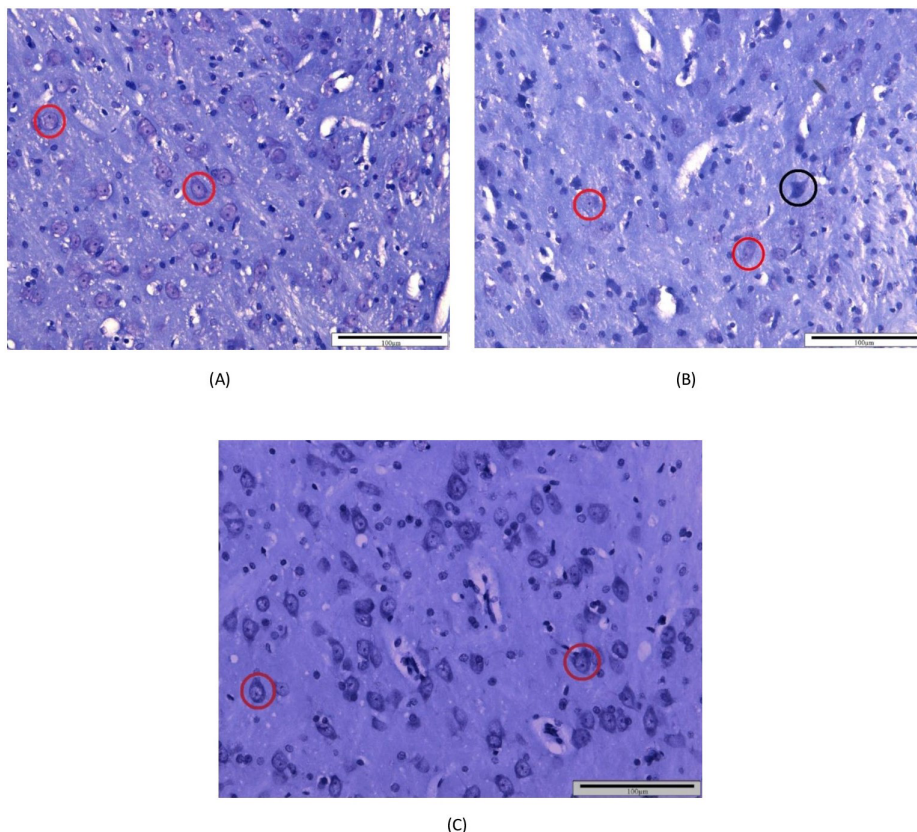


Figure 1: Histology of the left VPL of thalamus section of the offspring from (A) control (B) stress group and (C) stress treated with Tualang honey groups. (A) The neurons in red circles indicate the cells of interest. (B) The neurons in the red circle showed reduced staining intensity of the Nissl substances compared with the control group. Meanwhile, dark neuron in the black circle represents an injured neuron. (Nissl stain, magnification of x200, scale bar: 100µm). (C) The neurons demonstrated similar characteristics as in control group

Table III: Level of NMDA receptors among the groups

Group	Concentration (ng/ml) Mean ± SEM	95% CI	F-statistic (df)	p-value
Control	0.704 ± 0.067	0.541, 0.867	4.334 (2,18)	0.029*
Stress	1.033 ± 0.111*	0.761, 1.304		
Stress treated with Tualang honey	0.847 ± 0.045	0.736, 0.957		

One way ANOVA between groups analysis was applied followed by post-hoc multiple comparison using Bonferroni method

SEM: Standard error mean; CI: Confidence interval

*p<0.05 statistical comparison between stress and control groups.

DISCUSSION

The present study demonstrates marked differences in the nociceptive behaviour score in the prenatally stressed male rat offspring when compared between the groups. In formalin test, phase 1 is due to stimulation of nociceptors in the periphery while phase 2 is associated with persistent peripheral inflammation with central sensitization of dorsal horn neurons within the spinal cord (38, 39). The present report showed a higher nociceptive behaviour score at phase 1 and 2 in the offspring from stress group. The behaviour score was significantly lower in the rats' offspring from the stress group treated with Tualang honey. It was not known whether the lower nociceptive behaviour score was contributed by changes in the structure, oxidative stress or NMDA receptor level in the thalamus of the prenatally stressed rat offspring from treated group.

In this study, the stress group demonstrated a significant decrease in the number of Nissl-positive neurons in the VPL of prenatally stressed male rats' offspring compared to other groups. Along with that, the features of damaged neurons were observed in the offspring from the stress group. The presence of dark neurons indicates histological changes of injured neurons with massive shrinkage and abnormal basophilic internal granules (40). Therefore, these results suggest that prenatal stress was associated with structural changes in the VPL of the rats' offspring. Several studies have shown that oxidative tissue damage occur in various parts of the brain such as cerebral cortex, cerebellum, and hippocampus in the adult offspring exposed to prenatal stressed (41-43).

Animal studies have found that painful stimulation elevated the production of free radicals and lipid peroxidation (44, 45). Lipid peroxidation is one of the major mechanisms of cell membrane destruction and cell damage. One of the parameters that is frequently used as a marker for lipid peroxidation is MDA. In the present study, following formalin injection, a higher MDA level in VPL was shown in S group compared to other groups suggesting an increased oxidative stress in this group of rats. Zhu et al (2004) reported that prenatal stress was associated with increased ROS

and neuronal nitric oxide synthase expression in the hippocampus of rat offspring (41). Administration of Tualang honey in the pregnant dams was associated with reduced MDA level in VPL of prenatally stressed male rat offspring. The present work also demonstrated an increased level of CAT and SOD of the thalamus in SH group compared to S groups, suggesting increased antioxidant activity. Honey supplementation was shown to improve antioxidant activities e.g. CAT and SOD activities, in other conditions such as diabetic rats and stressed ovariectomised rats (46, 47). In the present study, administration of Tualang honey in the pregnant dams exposed to prenatal stress has also given similar results in the adult rat offspring. The antioxidants in the honey e.g. flavonoids might have been transferred to the developing foetus and produced long term beneficial effects (48).

Tualang honey contains non-enzymatic antioxidants such as Vitamins C and E which may interact to scavenge lipophilic and hydrophilic free-radical (49). Recently, a study done by Wu et al. (2017) reported that supplements of exogenous antioxidants, such as Vitamin E, would reverse the oxidative stress via replenishing the insufficiency of endogenous antioxidant in the offspring prenatally exposed to formaldehyde (50). Other reports also showed that administration of Vitamin E in pregnant rats and rabbits would protect the offspring from ethanol-induced oxidative stress and hypercholesterolemia respectively (49, 50).

In the present study, administration of Tualang honey in the pregnant dams has improved the activity of antioxidants and reduced the oxidant level in the rat offspring. However, the administration was not associated with reduction in the NMDA receptor level. A study done by Li et al., (2009) demonstrated that induction of formalin significantly increased the expression of NMDA receptor subtypes NR2A and NR2B, but not NR1 in rats forebrain, that may contribute to the pain-related aversion in male rats (52). The present study has measured the NMDA receptors level in the thalamus and has not looked at the various subtypes of NMDA. Among NMDA receptor subtypes, the NR2B is important for nociception (53). Therefore, for future studies, investigation of different subtypes of NMDA receptor is warranted. On the other hand, there is a possibility that at the dose of antioxidant used (1.2g/kg Tualang honey) is not effective to alter the NMDA receptor level. There is also a possibility that Tualang honey's action is not mediated by NMDA receptors but through inhibition of oxidative stress.

CONCLUSION

Prenatal stress was associated with increased nociceptive behaviour in the adult male rat offspring and it was accompanied with histological changes, oxidative stress and increased NMDA receptor level

in VPL of thalamus. Administration of Tualang honey was associated with decreased nociceptive behaviour and reduced histological changes and oxidative stress in the thalamus. In conclusion, this study suggests that the antioxidant effects of Tualang honey might have contributed to the modulation of nociceptive responses in formalin test of the prenatally stressed rat offspring.

ACKNOWLEDGEMENTS

This study was supported by Fundamental Research Grant Scheme (FRGS) (203/PPSP/6171162) awarded by Ministry of Education, Malaysia.

REFERENCES

- Glover V, Barlow J. Psychological adversity in pregnancy: what works to improve outcomes? *J Child Serv.* 2014; 9: 96-108.
- Betts KS, Williams GM, Najman JM, Alati R. The relationship between maternal depressive, anxious, and stress symptoms during pregnancy and adult offspring behavioral and emotional problems. *Depress Anxiety* 2015; 32: 82-90.
- Van den Hove D, Leibold N, Strackx E, Martinez-Claros M, Lesch KP, Steinbusch HW et al. Prenatal stress and subsequent exposure to chronic mild stress in rats; interdependent effects on emotional behavior and the serotonergic system. *Eur Neuropsychopharmacol.* 2014; 24: 595-607.
- Ronald A, Pennell CE, Whitehouse AJ. Prenatal maternal stress associated with ADHD and autistic traits in early childhood. *Front in psychol.* 2010 Oct 16; 1:223 doi: 10.3389/fpsyg.2010.00223.
- Matriciano F, Tueting P, Dalal I, Kadriu B, Grayson DR, Davis JM et al. Epigenetic modifications of GABAergic interneurons are associated with the schizophrenia-like phenotype induced by prenatal stress in mice. *Neuropharmacology.* 2013; 68:184-94.
- Abd Aziz CB, Ahmad R, Mohamed M, Wan Yusof WN. The effects of Tualang honey intake during prenatal stress on pain responses in the rat offsprings. *Eur J Integ Med.* 2013; 5(4): 326-31.
- Davis EP, Glynn LM, Waffarn F, Sandman CA. Prenatal maternal stress programs infant stress regulation. *J Child Psychol Psychiatry.* 2011; 52(2): 119-29.
- Wolff N, Darlington AS, Hunfeld J, Verhulst F, Jaddoe V, Hofman A et al. Determinants of somatic complaints in 18-month-old children: The generation study. *J Pediatr Psychol.* 2010; 35(3): 306-16.
- Maccari S, Darnaudery M, Morley-Fletcher S, Zuena AR, Cinque C, Van Reeth O. Prenatal stress and long-term consequences: implications of glucocorticoid hormones. *Neurosci and biobehav rev.* 2003; 27: 119-27.
- Sahu S, Madhyastha S, Rao G. Effect of prenatal stress on expression of glutathione system in neonatal rat brain. *Turk Neurosurg.* 2012; 22: 576-82.
- Halliwell B. Oxidative stress and neurodegeneration: where are we now? *J Neurochem.* 2006; 97:1634-58.
- Maur DG, Romero CB, Burdet B, Palumbo ML, Zorrilla-Zubilete MA. Prenatal stress induces alterations in cerebellar nitric oxide that are correlated with deficits in spatial memory in rat's offspring. *Neurochem Int.* 2012; 61:1294-301.
- Brittain MK, Brustovetsky T, Sheets PL, Brittain JM, Khanna R, Cummins TR et al. Delayed calcium dysregulation in neurons requires both the NMDA receptor and the reverse Na⁺/Ca²⁺ exchanger. *Neurobiol dis.* 2012; 46:109-17.
- Zohar I, Weinstock M. Differential Effect of Prenatal Stress on the Expression of Corticotrophin-Releasing Hormone and its Receptors in the Hypothalamus and Amygdala in Male and Female Rats. *J neuroendocrinol.* 2011; 23:320-328.
- Walf AA, Frye CA. Gestational or acute restraint in adulthood reduces levels of 5 α -reduced testosterone metabolites in the hippocampus and produces behavioral inhibition of adult male rats. *Front cell neurosci.* 2012; Dis 18, 6:40. doi: 10.3389/fncel.2012.00040
- Fleming DE, Anderson RH, Rhees RW. Effects of prenatal stress on sexually dimorphic asymmetries in the cerebral cortex of the male rat. *Brain res bull.* 1986; 16: 395-8.
- Abdul Aziz AA, Finn DP, Mason R, Chapman V. Comparison of responses of ventral posterolateral and posterior complex thalamic neurons in naive rats and rats with hindpaw inflammation: mu-opioid receptor mediated inhibitions. *Neuropharmacology.* 2005; 48: 607-16.
- Guilbaud G, Kayser V, Benoist JM, Gautron M. Modifications in the responsiveness of rat ventrobasal thalamic neurons at different stages of carrageenin-produced inflammation. *Brain Res.* 1986; 385:86-98.
- Kolhekar R, Murphy S, Gebhart G. Thalamic NMDA receptors modulate inflammation-produced hyperalgesia in the rat. *Pain.* 1997; 71: 31-40.
- Guilbaud G, Benoist JM, Jazat F, Gautron M. Neuronal responsiveness in the ventrobasal thalamic complex of rats with an experimental peripheral mononeuropathy. *J Neurophysiol.* 1990; 64:1537-54.
- Guilbaud G1, Benoist JM, Gautron M. Electrophysiological evidence that morphine can exert an antinociceptive effect in a neuropathic state: a study in the ventrobasal thalamus of rats after moderate ligation of one sciatic nerve. *Brain Res.* 1991; 551: 346-50
- Abd Aziz CB, Ismail CAN, Ibrahimi MI, Mohamed M, Hassan SK. Effects of different doses of Tualang

- honey on pain behaviour in rats with formalin-induced inflammation. *J Physiol Biomed Sci*. 2014; 27(2): 39-43.
23. Ismail CAN, Che Hussin CM, Mohamed M, Abd Aziz CB. Preemptive effects of administration of Tualang honey on inflammatory responses in adult male rats. *J Pharm Nutr Sc*. 2017; 7: 6-12.
 24. Khalil M, Alam N, Moniruzzaman M, Sulaiman S, Gan S. (2011). Phenolic acid composition and antioxidant properties of Malaysian honeys. *J Food Sci*. 2011; 76(6): C921-C928.
 25. Frankel S, Robinson G, Berenbaum M. Antioxidant capacity and correlated characteristics of 14 unifloral honeys. *Journal of Apicultural Research*. 1998; 37(1): 27-31.
 26. Mohamed M, Sirajudeen K, Swamy M, Yaacob M, Sulaiman S. Studies on the antioxidant properties of Tualang honey of Malaysia. *Afr J Tradit Complement Altern Med*. 2010; 7(1): 59-63.
 27. Nasir NAM, Halim AS, Singh KKB, Dorai AA, Haneef MNM. Antibacterial properties of tualang honey and its effect in burn wound management: a comparative study. *BMC Complement Altern Med*. 2010; 10(1): 31.
 28. Bashkaran K, Zunaina E, Bakiah S, Sulaiman SA, Sirajudeen K, Naik V. Anti-inflammatory and antioxidant effects of Tualang honey in alkali injury on the eyes of rabbits: experimental animal study. *BMC Complement Altern Med*. 2011; 11(1): 90.
 29. Fauzi AN, Norazmi MN, Yaacob NS. Tualang honey induces apoptosis and disrupts the mitochondrial membrane potential of human breast and cervical cancer cell lines. *Food Chem Toxicol*. 2011; 49(4): 871-78.
 30. Abd Aziz CB, Ahmad Suhaimi SQ, Hasim H, Ahmad AH, Long I, Zakaria R. Effects of Tualang honey in modulating nociceptive responses at the spinal cord in offspring of prenatally stressed rats. *J Integr Med*. 2019; 17 (1), 2019, 66-70
 31. Butkevich I, Mikhailenko V, Semionov P, Bagaeva T, Otellin V, Aloisi AM. Effects of maternal corticosterone and stress on behavioral and hormonal indices of formalin pain in male and female offspring of different ages. *Horm Behav*. 2009; 55:149-57.
 32. Abd Aziz CB, Ismail CAN, Hussin CMC, Mohamed M. The antinociceptive effects of Tualang honey in male Sprague-Dawley rats: a preliminary study. *J Tradit Complement Med*. 2014; 4(4), 298-302.
 33. Bayer SA, Altman J, Russo RJ, Zhang X. Timetables of neurogenesis in the human brain based on experimentally determined patterns in the rat. *Neurotoxicology*. 1993; 14(1), 83-114.
 34. Vinogradova E, Zhukov D, Batuev A. The effects of stages of the estrous cycle on pain thresholds in female white rats. *Neurosci behav physiол*. 2003; 33: 269-72.
 35. Haron MN, Rahman WFWA, Sulaiman SA, Mohamed M. Tualang honey ameliorates restraint stress-induced impaired pregnancy outcomes in rats. *Eur J Integr Med*. 2014; 6: 657-63.
 36. Dubuisson D, Dennis SG. The formalin test: a quantitative study of the analgesic effects of morphine, meperidine, and brain stem stimulation in rats and cats. *Pain*. 1977;4 :161-74.
 37. Paxinos G, Watson C. *The Rat Brain in Stereotaxic Coordinates*. 5th ed. Australia:Elsevier Academic Press, 2013.
 38. Shibata M, Ohkubo T, Takahashi H, Inoki R. Modified formalin test: characteristic biphasic pain response. *Pain*. 1989; 38: 347-52.
 39. Dickenson AH, Sullivan AF. Peripheral origins and central modulation of subcutaneous formalin-induced activity of rat dorsal horn neurones. *Neurosci Lett*. 1987; 83: 207-11.
 40. Ooigawa H, Nawashiro H, Fukui S, Otani N, Osumi A, Toyooka T et al. The fate of Nissl-stained dark neurons following traumatic brain injury in rats: difference between neocortex and hippocampus regarding survival rate. *Acta Neuropathol*. 2006; 112: 471-81.
 41. Zhu Z, Li X, Chen W, Zhao Y, Li H, Qing C et al. Prenatal stress causes gender-dependent neuronal loss and oxidative stress in rat hippocampus. *J Neurosci Res*. 2004; 78: 837-44.
 42. Flerov MA, Gerasimova IA, V'Yushina AV, Pritvorova AV. Effects of prenatal stress on free-radical lipid and protein oxidation and superoxide dismutase activity in cerebral cortex neurons and neuroglia in the rat brain. *Neurosci Behav Physiol*. 2009; 39: 371-5.
 43. Al-Amin MM, Alam T, Hasan SM, Hasan AT, Quddus AH. Prenatal maternal lipopolysaccharide administration leads to age- and region-specific oxidative stress in the early developmental stage in offspring. *Neuroscience*. 2016; 318: 84-93.
 44. Narenjkar J, Roghani M, Alambeygi H, Sedaghati F. The Effect of the Flavonoid Quercetin on Pain Sensation in Diabetic Rats. *BCN*. 2011; 2: 51-7.
 45. Rokyta R, Holecek V, Pekarkova I, Krejcov6 J, Racek J, Trefil L et al. Free radicals after painful stimulation are influenced by antioxidants and analgesics. *Neuro Endocrinol Lett*. 2003; 24: 304-9.
 46. Erejuwa O, Sulaiman S, Wahab M, Sirajudeen K, Salleh MM, Gurtu S. Antioxidant protection of Malaysian tualang honey in pancreas of normal and streptozotocin-induced diabetic rats. *Ann Endocrinol*. 2010; 71: 291-6.
 47. Al-Rahbi B, Zakaria R, Othman Z, Hassan A, Ahmad AH. Protective effects of Tualang honey against oxidative stress and anxiety like behaviour in stressed ovariectomised rats. *Int Sch Res Notices*. 2014; <http://dx.doi.org/10.1155/2014/521065> [21]
 48. Schroder-van der Elst JP, van der Heide D, Rokos H, Morreale de Escobar G, Kohrle J. Synthetic flavonoids cross the placenta in the rat and are

- found in fetal brain. *Am J Physiol.* 1998; 274: E253-6
49. Karajibani M, Hashemi M, Montazerifar F, Dikshit M. Effect of vitamin E and C supplements on antioxidant defense system in cardiovascular disease patients in Zahedan, southeast Iran. *J Nutr Sci Vitaminol.* 2010; 56: 436-40.
50. Wu D, Jiang Z, Gong B, Dou Y, Song M, Song X et al. Vitamin E Reversed Apoptosis of Cardiomyocytes Induced by Exposure to High Dose Formaldehyde During Mice Pregnancy. *Int Heart J.* 2017; 58: 769-77.
51. Palinski W, D'Armiento FP, Witztum JL, de Nigris F, Casanada F, Condorelli M et al. Maternal hypercholesterolemia and treatment during pregnancy influence the long-term progression of atherosclerosis in offspring of rabbits. *Circ Res.* 2001; 89: 991-6.
52. Li TT, Ren WH, Xiao X, Nan J, Cheng L-Z, Zhang X-H et al. NMDA NR2A and NR2B receptors in the rostral anterior cingulate cortex contribute to pain-related aversion in male rats. *Pain.* 2009; 146: 183-93.
53. Petrenko AB, Yamakura T, Baba H, Shimoji K. The role of N-methyl-D-aspartate (NMDA) receptors in pain: a review. *Anesth & Analg* 2003; 97: 1108-16.