

CASE REPORT

Lower Midline Syndrome with Undescended Testes in the Tobacco Agricultural Environment: A Case Report

Henggar Allest Pratama¹, Lukman Oktadianto², Supangat^{3,4,5}

¹ Emergency Department, Dr. Soebandi Hospital, Jember 68111, Indonesia

² Department of Pediatric, Dr. Soebandi Hospital, 68111 Jember, Indonesia

³ Pharmacology Department, Faculty of Medicine, Jember University, Jember 68121, Indonesia

⁴ Molecular Biology Research Center, Jember University, Jember 68121, Indonesia

⁵ Department of Surgery, Dr. Soebandi Hospital, 68111 Jember, Indonesia

ABSTRACT

Lower midline syndrome is a rare congenital anomaly associated with omphalocele. Undescended testes is a congenital absence of one or both testes in the scrotum. Both of lower midline syndrome and undescended testes incidence have a positive correlation with exposure of cigarette and pesticide. Tobacco agricultural environment is a vulnerable area exposed by pesticides and cigarettes. This is the case report to associated tobacco agricultural environment's exposure with lower midline syndrome and undescended testes. We describe a case of lower midline syndrome and undescended testes that occurs in the tobacco agricultural environment. In this case we found the exposures of paternal heavy smoker, second-hand smoker, pesticides from tobacco agricultural environment and daily use of bug spray in the house. As conclusion, the exposures from tobacco agricultural environment may take a contribution to lower midline syndrome and undescended testes incidence.

Keywords: Lower midline syndrome, Omphalocele, Undescended testes, Tobacco agricultural environment

Corresponding Author:

Supangat, PhD

Email: drsupangat@unej.ac.id

Tel: +6285655860096

INTRODUCTION

Omphalocele is a congenital anomaly of abdominal wall defect that allow abdominal viscera's herniation into the umbilical ring covered by peritoneum, amnion and Wharton's Jelly. In omphalocele, the incidence of multiple congenital anomaly varies from 35 to 81%, one of them is lower midline syndrome. Lower midline syndrome described as the combination of an omphalocele, bladder exstrophy (or cloaca exstrophy), imperforate anus, and spinal defects. Lower midline syndrome is very rare and may have an incidence of 1 in 200,000 to 400,000 live births (1). Undescended testes are a congenital absence of one or both testes in the scrotum. Recent prospective study has described one third of premature boys have undescended testes at least on one side.

Both of lower midline syndrome and undescended testes incidence have a positive correlation with exposure of cigarette and pesticide. Tobacco agricultural environment is a vulnerable area exposed by pesticides and cigarettes. We describe a case of lower midline syndrome and undescended testes that occurs in the

tobacco agricultural environment.

CASE REPORT

This male baby was born by normal labor to a gravida 1, para 0, abortus 0, 23 years old female at 27-28 weeks gestational age. APGAR score was 7-8. The baby's birth weight was 2000 grams and the body's length was 46 cm. In the anterior abdomen, an omphalocele was visible with a defect at the bottom. Urine and meconium discharged out from the defect. There was an epispadias penis, no testes in the scrotum and no anal hole (Figure 1). Vertebrae anomaly was not found. Afterwards, the patient planned to a cito exploratory laparotomy by a pediatric surgeon due to risk of infection and dehydration increases with time.

After the exploration, cloaca exstrophy was found. The colon was almost not formed. Only a small part of the colon directly connected to the small intestine (Figure 2). We also found both of testes in the abdominal cavity with the gubernaculum testes clearly visible (Figure 3). Then, we made an end type ileostomy, closure the defect, repair the cloaca extrophy and placing NTG tube number 3,5 to drainage the urine, and put on a stoma bag. We didn't repair the epispadias and abdominal testes (Figure 4). In the postoperative procedure, the patient was treated intensively in the NICU room with medication (Cefotaxime 100 mg/12

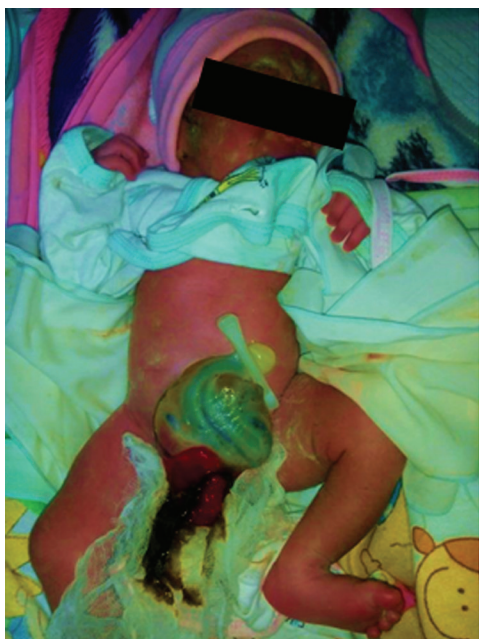

Figure 1: The patient's condition when he first arrives in the emergency room Soebandi Hospital. There was an omphalocele with meconium (and urine) discharged out from the defect.

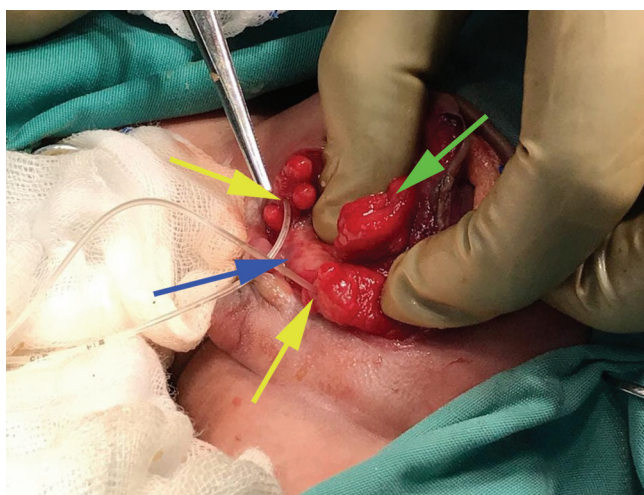


Figure 2: Identification during the operation. We can see the NTGs inserted to the ureter hole (yellow arrow), the cloaca exstrophy (blue arrow) and the distal part of the colon (green arrow).

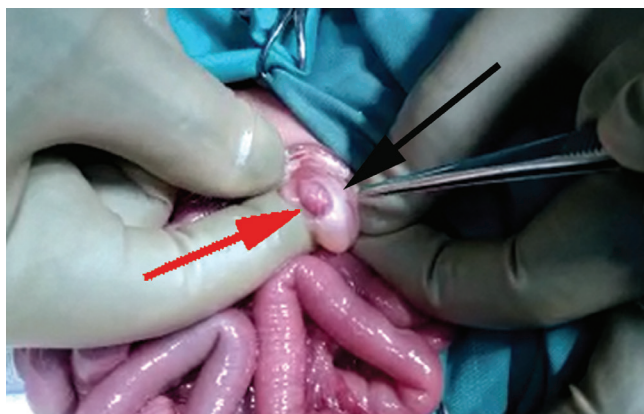


Figure 3: The testes (black arrow) and the gubernaculum (red arrow) in the abdominal cavity.

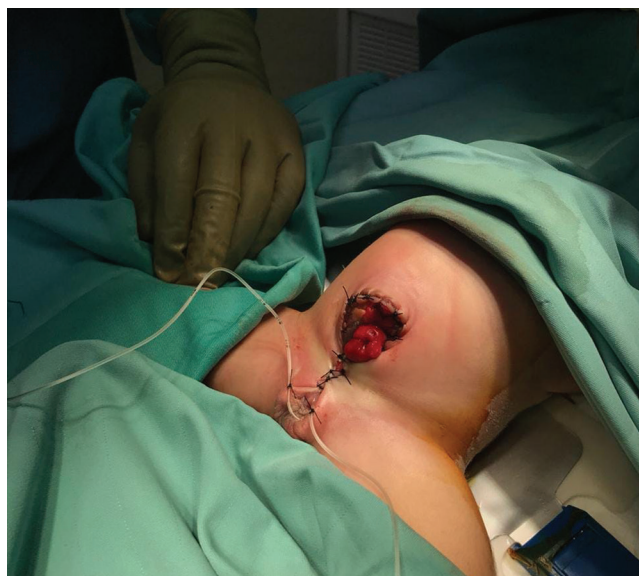

Figure 4: Post-operative condition

hours, Metronidazole 14 mg/8 hours, Paracetamol 25 mg/8 hours, monitoring fluid and electrolytes) and take oral breast milk gradually. The result was good. There was no postoperative complication. On the 6th day postoperative, patients could be transferred to the perinatology room and the intake gradually increased. At the 10th day, the patient condition was good and has an adequate intake so patient could take home medication. One month later, the patient condition was good, good function of ileostomy, no postoperative complication and the baby weight was increased.

The mother of our patient lived with her husband. The patient's socioeconomic was from low educated and low-middle economic class. Her husband is a heavy smoker, he smokes two packs cigarettes every day. He often smokes in the house and inhale by his wife. He worked in the tobacco processing unit. His clothes were not washed separately. Their home was in the tobacco agricultural area. Around the patient's home, there was the tobacco farming fields that use pesticides every 2 or 3 months. They consumed water from a house well, five meters near the tobacco farming field. The pesticide's content in the water has never been checked. They reported many insects investing to the house so they used a bug spray daily. They used two bottles (each bottle contains 720 ml volume) bug spray every week. It was used before and during pregnancy.

DISCUSSION

The study about association between second-hand smoker and paternal smoker with omphalocele is still limited. However, there was possible association between omphalocele and periconceptual exposure of second-hand smoker (2).

There is a positive correlation between smoker and undescended testes. A significant increased risk reported

from study of correlate between passive smoker during pregnancy and paternal smoker with undescended testes incidence. Passive smoker during pregnancies is 1.48 more risky to have children with undescended testes. Paternal smoker before and during pregnancy is more risky too (1.87 before pregnancy and 1.92 during pregnancy) (3).

The mother of our patient might has been exposed to pesticides from the husband's clothes, from water soil near the tobacco field, and the air inhaled by the patient in tobacco agricultural environment. The most used pesticide in tobacco agricultural environment is herbicide and insecticide. Herbicide contains atrazine, while insecticide contains organochlorine and organophosphate. Exposure of pesticides has been linked to increase risk of birth defects. Exposures of pesticide during the 3rd to 8th weeks of pregnancy have a high risk to fetal death due to congenital anomaly. A significant association reported from study of correlate between maternal residential proximity within 1.000 meters of agricultural pesticide application with neural tube defect in children. High level of atrazine and nitrate correlate with increased incidence of abdominal wall defects. These combinations could inhibit the cell proliferation of embryogenesis by interrupting the certain molecular mRNA signal that lead to abdominal wall defect (4).

A similar case about correlation between bug spray daily use and birth defect has been reported. A case of bladder exstrophy and undescended testes with bug spray's exposure has been report. They use one bottles of bug spray every two days (1000 cc every two days) contain pyrethroids and pyriproxyfen to treat cockroach infestation in their home. The examinations of urine sample of the patient successfully detect the substance content of pyrethroids and pyriproxyfen. It suggests that bug spray daily use has association with multiple congenital anomalies (5). Our finding support that suggestion.

CONCLUSION

In conclusion, we describe a rare congenital anomaly case of lower midline syndrome with undescended testes in the tobacco agricultural environment. This is

the case of major birth defect with multiple congenital anomalies. The prognosis was depending on family care and health care to prevent infection and adequate nutrition. In this case we found the exposures of paternal heavy smoker, second-hand smoker, pesticides from tobacco agricultural environment and daily use of bug spray in the house since preconception. The exposures from tobacco agricultural environment may take a contribution to lower midline syndrome and undescended testes incidence.

ACKNOWLEDGEMENT

The authors wish to thank all medical staff in Soebandi Jember Hospital and all committee of 3rd ISCADB Yogyakarta 2019.

REFERENCES

1. Keppler-Noreuil KM. OEIS complex (omphalocele-exstrophy-imperforate anus-spinal defects): A review of 14 cases. *American journal of medical genetics*. 2001; 99(4): 271-9.
2. Feldkamp ML, Srisukhumbowornchai S, Romitti PA, Olney RS, Richardson SD, Botto LD. National Birth Defects Prevention Study. Self-reported maternal cigarette smoke exposure during the periconceptional period and the risk for omphalocele. *Paediatric and perinatal epidemiology*. 2014, 28(1): 67-73.
3. Kurahashi N, Kasai S, Shibata T, Kakizaki H, Nonomura K, Sata F, et al. Parental and neonatal risk factors for cryptorchidism. *Medical science monitor*. 2005; 11(6): 274-83.
4. Sharma S, Uggini GK, Patel V, Desai I, Balakrishnan S. Exposure to sub-lethal dose of a combination insecticide during early embryogenesis influences the normal patterning of mesoderm resulting in incomplete closure of ventral body wall of chicks of domestic hen. *Toxicology reports*. 2018; 5: 302-8.
5. Martin M, Rodriguez K, S6nchez-Sauco M, Zambudio-Carmona G, Ortega-Garcia JA. Household exposure to pesticides and bladder exstrophy in a newborn baby boy: a case report and review of the literature. *Journal of medical case reports*. 2009; 3(1): 6626.