

## CASE REPORT

# A Fatal Case of Rhinocerebral Mucormycosis

Nurul Suhaili Kamarudin<sup>1,2</sup>, Rosni Ibrahim<sup>1</sup>, Nur Hanani Ahmad<sup>2</sup>, Siti Norbaya Masri<sup>1</sup>

<sup>1</sup> Department of Medical Microbiology and Parasitology, Faculty of Medicine and Health Science, Universiti Putra Malaysia, 43400 Serdang, Selangor, Malaysia

<sup>2</sup> Microbiology Unit, Department of Pathology, Hospital Sungai Buloh, Jalan Hospital, 47000 Sungai Buloh, Selangor, Malaysia

### ABSTRACT

Rhinocerebral mucormycosis is a potentially fatal and progressive angioinvasive fungal infection. It is classically described in patients with uncontrolled diabetes mellitus and hematological malignancies. This report describes a case of progressive rhinocerebral mucormycosis in a patient with poorly controlled diabetes who was on prolonged prednisolone therapy for autoimmune kidney disease. The patient, who was a female, presented to hospital with headache, orbital pain and nasal bridge swelling. Black eschar on nasal mucosae was present on admission. Later, she was started on intravenous fluconazole for the diagnosis of fungal sinusitis. Subsequently, she developed intracerebral haemorrhage complicated with transtentorial herniation. Diagnosis of rhinocerebral mucormycosis was later observed by a laboratory finding and the treatment was changed to intravenous amphotericin B. However, the patient succumbed to her illness on the 6<sup>th</sup> day of hospitalisation. This report discusses the risk factors associated with rhinocerebral mucormycosis as well as the underlying pathogenesis. This report will also highlight the importance of early diagnosis and appropriate treatment for mucormycosis to improve prognosis in patients.

**Keywords:** Mucormycosis, Rhinocerebral, Risk factors, *Rhizomucor* sp.

### Corresponding Author:

Siti Norbaya Masri, MPath

Email: sitinorbaya@upm.edu.my

Tel: +603-9769 2370

### INTRODUCTION

Mucormycosis is frequently a life-threatening infection caused by one of the members of Mucoraceae family, including *Lichtheimia*, *Mucor* and *Rhizopus* sp. The mortality rate of mucormycosis remains high between the range of 24% to 49% despite surgical management and appropriate antifungal therapy (1). Spectrum of mucormycosis ranges from cutaneous, rhinocerebral, and sinopulmonary to disseminated (2). Classically, these infections occur in individuals with altered host defense and those that have been associated with uncontrolled diabetes mellitus with or without ketoacidosis, neutropenia, treatment with corticosteroid, organ and bone marrow transplants, trauma and burns, malignant haematological diseases, iron overload, and deferoxamine therapy (3). As mucormycosis is a rapidly progressive infection, failure to recognise and delay in treatment of this fungal infection will increase the risk of adverse clinical outcomes.

### CASE REPORT

A 52-year-old female patient was presented to the Emergency Department with a chief complaint of facial

pain and swelling over the nasal bridge and periorbital region for one week. It was associated with headache, fever and lethargy. Her medical history revealed that she had type 2 diabetes mellitus, hypertension and autoimmune kidney disease for five years. She was also on prednisolone for the past one year for autoimmune kidney disease.

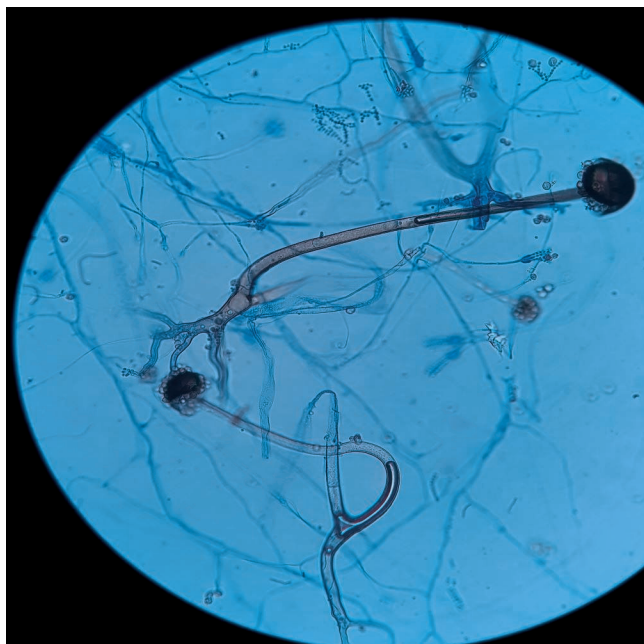
On examination, there was a diffuse erythematous facial swelling over the nasal bridge extending bilaterally to the maxillary and infraorbital regions. On palpation, the swelling was tender and soft in consistency. Both eye movements were normal, and the pupils were reactive. There was no diplopia, ptosis, and proptosis. Endoscopic examination of nasal cavity revealed a presence of black crust at the inferior turbinate and vestibule, medial turbinate, and septum of the right nasal cavity. The left nasal cavity was unable to be visualised due to severe congestion. No abnormality was detected from the oral cavity examination. Examination of other body systems was unremarkable.

Vital signs upon presentation were otherwise normal. Laboratory investigation on admission demonstrated leukocytosis with neutrophilia (white cell counts  $21.9 \times 10^9/L$ , neutrophils 74%), uncompensated metabolic acidosis (pH 7.317,  $HCO_3^-$  20.8, lactate 1.4), hyperglycaemia (random blood glucose 16.8mmol/L), and glycosuria. However, diabetic ketoacidosis was unlikely because ketone was not detected. Blood urea

nitrogen was 38.8 mmol/L, and creatinine 460 µmol/L. Her coagulation tests were within the normal limits. Based on the history and clinical findings, a provisional diagnosis of fungal sinusitis was made, followed by the empirical therapy with intravenous fluconazole 200 mg once daily.

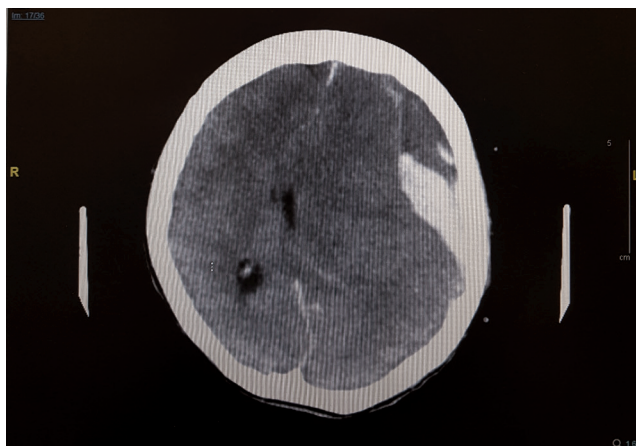
Computed tomography (CT) scan revealed the mucosal thickening of bilateral frontal, ethmoid and maxillary sinuses, thickening of left eye preseptal soft tissue, and deviation of nasal septum to the left. The brain parenchyma was normal, and no focal-enhancing lesion found. Subsequently, endoscopic sinus surgery was done. Intraoperatively, there was an extensive fungal sinusitis involving nasal cavity, septum and all paranasal sinuses with pus and black eschar. The lesion was extending into the base of the skull at bilateral orbital lamina of ethmoid bone. Removal of necrotic tissue and debridement of sinus cavity were performed. Pus and tissue sample were sent to the microbiology laboratory.

Fungal culture grew mould after a-three day incubation period. Based on macroscopic and microscopic characteristics, it was identified as *Rhizomucor sp.* (Fig.1). However, no confirmation test by molecular method was done. Following the microbiology result, the antifungal agent was changed from fluconazole to intravenous amphotericin B.



**Figure 1: Photomicrograph of Lactophenol cotton blue stained of fungal colony (magnification x 400). *Rhizomucor sp.* was identified.**

However, despite the change of antifungal therapy, the patient's condition worsened with GCS E2M1VT. Urgent computed tomography scan of the brain and paranasal sinuses revealed new large fronto-temporo-parietal extra-axial hematoma with acute bleed component, causing significant mass effect, midline shift and cerebral oedema. There was also evidence of



**Figure 2: Urgent Computed tomography of brain. Large left fronto-temporo-parietal extra-axial hematoma, midline shift and cerebral oedema.**

transtentorial herniation and worsening of pansinusitis (Fig.2). She passed away within 24 hours after the event.

## DISCUSSION

The most common genus associated with mucormycosis are those of genera *Rhizopus sp*, *Lichtheimia* and *Mucor* (2). The incidence rate of rhinocerebral mucormycosis was reported as 1.7 cases per million people per year in the United States (2). Although mucormycosis can manifest in a variety of clinical forms, rhinocerebral mucormycosis found is predominantly associated in patients with poorly controlled diabetes mellitus and diabetic ketoacidosis (2). Diabetes mellitus was found to be the underlying illness in about 66% of patients with rhinocerebral mucormycosis (4).

When infected, the phagocytes will move towards and kill the microorganism by oxidative as well as nonoxidative mechanisms. This ability is impaired in patients with hyperglycemia and acidosis. Other than that, patients with systemic acidosis have elevated level of available serum iron. Low pH state will cause proton-mediated displacement of ferric iron ( $Fe^{3+}$ ) from serum carrier molecules. Then, at the cell surface of mucorales, ferric iron ( $Fe^{3+}$ ) is reduced to ferrous iron ( $Fe^{2+}$ ). Iron is needed for the growth of mucorales in serum (3).

In this case, it was presumed that uncontrolled diabetes and prolonged prednisolone therapy have predisposed the patient to mucormycosis, particularly in rhinocerebral form. High glucose and iron concentrations will induce the expression of glucose-regulated protein 78 (GRP78). GRP78 was identified as the host receptor in endothelial cells which mediates the invasion and damage of human endothelial cells (3).

Rhinocerebral mucormycosis is believed to have begun with the inhalation of spores into paranasal sinuses of susceptible host. The infection usually manifests as acute sinusitis. Patient often complains of nasal congestion, fever, headache, sinus pain, and

purulent nasal discharge. After all sinuses are affected, the infection will spread to the contiguous structures, such as orbit, palate and brain (2). The angioinvasion properties of mucorales which causes purulent arteritis and thrombosis, can result in fatal strokes, and patient can present with acute subdural hematoma, massive intracerebral haemorrhage, and basal ganglia bleed (2). The patient in this case study displayed no signs of central nervous system involvement on initial presentation. Infection might be rapidly progressed and directly spread, involving central nervous system in a few days, that resulted in intracerebral haemorrhage complication with transtentorial herniation.

Surgical debridement is strongly recommended to be combined with antifungal therapy in patient with mucormycosis. There are two systemic antifungal therapies currently available with good activity toward mucormycosis: amphotericin B and triazole posaconazole. However, the use of amphotericin B deoxycholate is discouraged due to its toxicity (1). Meanwhile, the posaconazole has enhanced in vitro activity against mucormycosis (1).

There was a delay in proper treatment of mucormycosis in this case. An initial diagnosis of fungal sinusitis was established, and patient was treated empirically with intravenous fluconazole which has no reliable activity against mucormycosis (1). Early recognition of mucormycosis and rapid initiation of appropriate antifungal therapy together with surgical debridement are important in improving patient survival before angioinvasion, necrosis and dissemination of mucormycosis to other organs (5).

Underlying poorly controlled diabetes mellitus and black eschar during endoscope examination and surgery should prompt a high index of suspicion for mucormycosis and treatment with proper antifungal therapy should begin without waiting for the culture result. For this patient, early administration of appropriate antifungal therapy combined with surgical debridement might have prevented the progression of mucormycosis into her central nervous system.

## CONCLUSION

Mortality rate of rhinocerebral mucormycosis is high

despite the surgical debridement and antifungal therapy. Underlying comorbidities, clinical features, and physical examination of patient should prompt a high index of suspicion for mucormycosis. In conclusion, clinician's awareness, early initiation of appropriate antifungal agent, and surgical intervention represent the effective management of mucormycosis.

## ACKNOWLEDGEMENT

We would like to thank the Director General of Health Malaysia for his permission to publish this case report.

## REFERENCES

1. Cornely OA, Arikan-Akdagli S, Dannaoui E, Groll AH, Lagrou K, Chakrabarti A, et al. ESCMID + and ECMM joint clinical guidelines for the diagnosis and management of mucormycosis 2013. 2014 [cited 2019 Mar 7]; Available from: [https://www.clinicalmicrobiologyandinfection.com/article/S1198-743X\(14\)60228-7/pdf](https://www.clinicalmicrobiologyandinfection.com/article/S1198-743X(14)60228-7/pdf)
2. Petrikkos G, Skiada A, Lortholary O, Roilides E, Walsh TJ, Kontoyiannis DP. Epidemiology and Clinical Manifestations of Mucormycosis. *Clin Infect Dis* [Internet]. 2012 Feb 1 [cited 2019 Feb 20];54(suppl\_1):S23–34. Available from: [http://academic.oup.com/cid/article/54/suppl\\_1/S23/284492/Epidemiology-and-Clinical-Manifestations-of](http://academic.oup.com/cid/article/54/suppl_1/S23/284492/Epidemiology-and-Clinical-Manifestations-of)
3. Ibrahim AS, Spellberg B, Walsh TJ, Kontoyiannis DP. Pathogenesis of Mucormycosis. *Clin Infect Dis* [Internet]. 2012 Feb 1 [cited 2019 Feb 20];54(suppl\_1):S16–22. Available from: [http://academic.oup.com/cid/article/54/suppl\\_1/S16/284344/Pathogenesis-of-Mucormycosis](http://academic.oup.com/cid/article/54/suppl_1/S16/284344/Pathogenesis-of-Mucormycosis)
4. Rees JR, Pinner RW, Hajjeh RA, Brandt ME, Reingold AL. The epidemiological features of invasive mycotic infections in the San Francisco Bay area, 1992-1993: results of population-based laboratory active surveillance. *Clin Infect Dis* [Internet]. 1998 Nov [cited 2019 Feb 21];27(5):1138–47. Available from: <http://www.ncbi.nlm.nih.gov/pubmed/9827260>
5. Kontoyiannis DP, Lewis RE. How I treat mucormycosis. *Blood* [Internet]. 2011 Aug 4 [cited 2019 Jun 21];118(5):1216–24. Available from: <http://www.ncbi.nlm.nih.gov/pubmed/21622653>