

CASE REPORT

Wandering Spleen as a Cause of Acute Abdomen: A Surgical Conundrum from Acute Appendicitis to Splenic Torsion and Ischemic Small Bowel Volvulus

Fatimah Najid¹, Sanjeev Sandrasecra¹, Mohd Zuki Asyraf¹, Chang Haur Lee¹, Firdaus Hayati², Nornazirah Azizan³, Andee Dzulkarnaen Zakaria⁴

¹ Department of Surgery, Queen Elizabeth Hospital, Ministry of Health Malaysia, Kota Kinabalu, Sabah, Malaysia

² Department of Surgery, Faculty of Medicine and Health Sciences, Universiti Malaysia Sabah, Kota Kinabalu, Sabah, Malaysia

³ Department of Pathobiology and Medical Diagnostic, Faculty of Medicine and Health Sciences, Universiti Malaysia Sabah, Kota Kinabalu, Sabah, Malaysia

⁴ Department of Surgery, School of Medical Sciences, Universiti Sains Malaysia, Kota Bharu, Kelantan, Malaysia

ABSTRACT

Wandering spleen is renowned as a surgical enigma due to its diverse presentations. Due to lack of its attaching ligaments which would usually place it at the left hypochondrium region, the spleen 'wanders' and may be located anywhere within the abdominal cavity. This condition has been associated with many complications such as splenic torsion, pancreatitis and portal hypertension. We report a case of a wandering spleen presenting as acute appendicitis in an 18-year-old young active sportsman. The patient developed post-operative ileus and later intestinal obstruction which necessitated exploratory laparotomy onto which the final diagnosis of splenic and small bowel infarct due to splenic torsion with small bowel volvulus was made. Splenectomy, small bowel resection and primary anastomosis were performed and the patient made a full recovery.

Keywords: Wandering spleen, Appendicitis, Intestinal obstruction, Volvulus

Corresponding Author:

Firdaus Hayati, DrGenSurg

Email: firdaushayati@gmail.com

Tel: +6088-320000 ext 611701

INTRODUCTION

Wandering spleen is widely known as a surgical enigma due to its diverse presentations. In a normal person, the attaching ligaments namely the lienorenal, splenicocolic, splenophrenic, gastrosplenic and phrenicocolic ligaments hold the spleen in its usual anatomical position in the left hypochondrium (1). Absence of the above mentioned ligaments therefore allows the spleen to be freely mobile in the abdominal cavity and mostly found in the pelvis (2). Due to this mobility derived from its long mesentery, patients usually present with splenic torsion (1). We present a patient with wandering spleen who initially presented with an acute abdomen mimicking acute appendicitis and had later developed small bowel obstruction and ischemia secondary to splenic torsion and small bowel volvulus. As far as are concerned, this is the first case of wandering spleen with various concomitant presentations.

CASE REPORT

An 18-year-old active sportsman presented with typical

presentation of acute appendicitis with a migratory pain to right iliac fossa of 3-day duration. Clinical examination showed McBurney's point tenderness with localised peritonism suggestive of perforation. Full blood count revealed a leucocytosis of $18 \times 10^3/\mu\text{L}$ while other routine investigations were unremarkable. This then led our team to perform an open appendicectomy via a Lanz incision. Intra-operatively, the diagnosis of appendicitis was confirmed whereby the appendix appeared acutely inflamed but there being no perforation. Limited exploration of the ileum up to 60 cm was unremarkable. Incidentally, it was found that an intra-abdominal mass suggestive of a wandering spleen was found in the lower abdomen in the suprapubic region. However, due to consent for splenectomy not obtained prior to surgery and the appearance of the spleen which looked viable, a splenectomy was not performed during the surgery.

Post-operatively, the pain score of the patient had reduced drastically but he started to develop ileus. In lieu of a relatively straightforward appendicectomy with low risk of post-operative complications, a contrast-enhanced computed tomography (CECT) scan of abdomen and pelvis was performed after failure of conservative management with bowel rest. The CECT showed dilated small bowels and confirmed the presence of a wandering spleen in the suprapubic region that was in line with intraoperative findings

(Figure 1a and 1b). However, the spleen was viable with no mechanical obstruction. Following the next few days of bowel rest and gradual reintroduction of oral feeding, the patient soon improved and was discharged home with an elective date for splenectomy in anticipation of the well-known complications of wandering spleen.

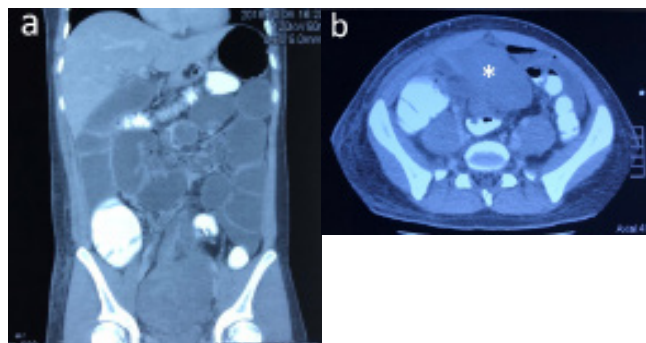


Figure 1: (a) Coronal view of CECT showing atypical spleen in the suprapubic area with absence of whirl-pool sign to suggest of splenic torsion. (b) Axial view of CECT confirming the pelvic spleen (*).

On the 10th post-operative day, he presented to us again with signs of acute intestinal obstruction. Examination of his abdomen revealed a distended abdomen with generalised tenderness and guarding over the lower abdomen. Blood investigation showed leucocytosis of $22 \times 10^3/\mu\text{L}$ and thrombocytosis of $1311 \times 10^6/\mu\text{L}$. Plain abdominal radiograph showed dilated small bowels with multiple air-fluid levels. He was then scheduled for emergent exploratory laparotomy due to the impression of post-operative adhesive obstruction and possibility of torsion of the wandering spleen. Intra-operatively, it was found that the mesentery of the spleen had become entangled with a segment of ileum leading to volvulus and ischemia with splenic infarction (Figures 2a and 2b). There were unusually dense adhesions and a poor surgical plane between the splenic mesentery and affected small bowels. Splenectomy and small bowel resection with primary end-to-end anastomosis were performed. The patient had a slow but eventual recovery one week after surgery and was discharged well after completing his influenza, pneumococcal and meningococcal vaccinations. The appendix, small bowel resection specimens and spleen were sent for histopathological examination. The histology of the appendix specimen showed peri-appendicitis whereas the spleen was indeed infarcted. During his subsequent follow-ups, he was cheerful, able to perform his usual physical and daily activities and was put on prophylactic antibiotics.

DISCUSSION

Wandering spleen has been found to be the cause of a myriad of conditions. They include acute to chronic abdominal pain, recurrent pancreatitis and concomitant existence with congenital pathology such as horseshoe kidney (3). Physical examination of the abdomen would

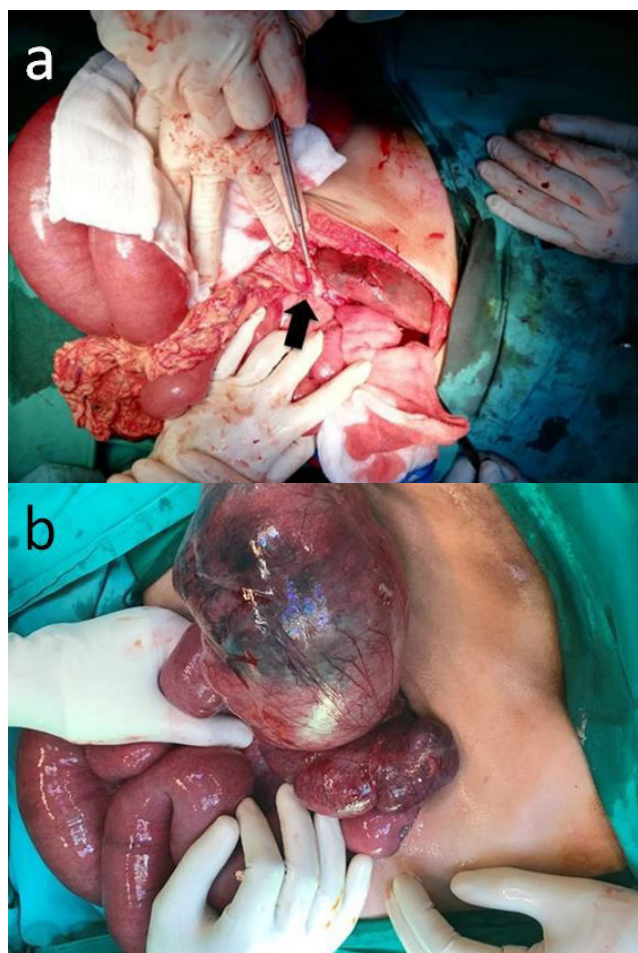


Figure 2: (a) Intra-operative picture showing splenic pedicle (black arrow) and the adhered bowel causing an internal herniation and strangulation of small bowel. (b) Intra-operative picture showing haemorrhagic and ischemic changes of the spleen.

alert the clinician to abdominal mass frequently but not limited to the lower abdomen. This mass would be firm, well-defined borders and shape, and relatively mobile. However, in the presence of an acute abdomen, physical examination would be less helpful due to tenderness and guarding in the abdomen preventing a proper assessment and delineation of the mass. In our patient, the symptoms mimicking acute appendicitis had reduced the likelihood of picking up the wandering spleen in the suprapubic region due to pain and guarding in the lower abdomen.

Blood investigations are usually non-specific and do little to aid in the diagnosis of a wandering spleen which was evident in our case. Leucocytosis occurs as a result of inflammation and the development of thrombocytosis would probably be attributed to splenic infarction in our patient.

Radiological investigations are the main adjuncts which would aid in the confirmation of the diagnosis. Ultrasonography is commonly employed as the first line imaging modality and would show the absence of the

spleen in the left hypochondrium and help localise the spleen in its present location. Duplex ultrasound of the pedicle and mesentery could help assess the viability of the spleen or the presence of torsion. However, the sensitivity of ultrasonography is variable as it is operator dependent (4). CECT of the abdomen eliminates the operator variability of ultrasonography, provides similar information pertaining to location of the spleen and identifies other associated pathologies in the abdomen (3). Contrast enhancement and vascularity visualized on CECT would also assist the clinician in diagnosing splenic torsion and therefore direct the type of surgery to be performed, be it splenopexy if viable or splenectomy if infarcted (4).

Wandering spleen per se is not a harmful condition but non-intervention may increase the risk of complications. In an asymptomatic patient, elective splenopexy is the surgery of choice. Various methods of splenopexy have been described: either an open or laparoscopic approach, using a retroperitoneal pouch or mesh fixation (sandwich method) (5). However, the feasibility of splenopexy is dependent on factors such as viability, presence of varicosities or any other evidence of portal hypertension and the anatomical practicality of relocating the spleen to left hypochondrium. It is therefore imperative that prior to any decision on splenopexy or splenectomy of an asymptomatic wandering spleen, the clinician should discuss with and counsel the patient on the benefits and risks of each surgery. In a patient with high risk of torsion due to physical activity as was the case in our patient whom he is an active rugby player, the decision was made for him to undergo a splenectomy to eliminate the risk of haemorrhage and torsion following trivial trauma to the abdomen.

It was unfortunate that in our patient the appendix that appeared inflamed was a red herring to the underlying complications caused by a wandering spleen. The cause of post-operative ileus was further confounded by a CECT scan that showed a viable spleen with no identifiable cause for the small bowel dilatation. The recurrence of symptoms eventually necessitated an exploratory laparotomy and the presence of extremely dense adhesion with poor surgical plane postulates to the possibility of chronic intermittent intestinal

obstruction and ischemia which might have resulted in the initial presentation. Later, it progressed onto a complete splenic infarction and bowel ischemia, which may or may not have been the direct consequence of the first surgery.

CONCLUSION

The wandering spleen like its namesake may be found in any location in the abdominal cavity, associated with it often perplexing presentations to the surgical emergency unit. Wandering spleen remains a rare cause of intestinal obstruction and a high index of suspicion is required to diagnose wandering spleen, identification of which is aided primarily by imaging modalities such as ultrasonography and CECT scan. In the acute abdomen, surgical approach is usually centred towards the primary pathology. Decision for spleen conserving versus splenectomy needs to be individualised.

ACKNOWLEDGEMENTS

We would like to thank the Director General of Health Malaysia for giving the permission to publish this article. The authors claim to have no financial interest in the commercial products in this study.

REFERENCES

1. Hui Lian H, Hayati F, Ali AA, Azizan N, Che Ani MF, Suhaili MA, et al. Wandering spleen: a unique cause of acute abdomen. *Folia Morphol (Warsz)*. 2018;77(2):400-402.
2. Viana C, Cristino H, Veiga C, Lero P. Splenic torsion, a challenging diagnosis: Case report and review of literature. *Int J Surg Case Rep*. 2018;44:212-216.
3. Than DJ, Ern TT, Karim KBA. Wandering spleen with horseshoe kidney a rare occurrence. *Int J Surg Case Rep*. 2018;45:96-100.
4. Priyadarshi RN, Anand U, Kumar B, Prakash V. Torsion in wandering spleen: CT demonstration of whirl sign. *Abdom Imaging*. 2013;38(4):835-8
5. Palanivelu C, Rangarajan M, Senthilkumar R, Parthasarathi R, Kavalakat AJ. Laparoscopic mesh splenopexy (sandwich technique) for wandering spleen. *JLS*. 2007;11(2):246-51.