

CASE REPORT

Cryptococcal Meningitis in an Immunocompetent Swiftlet Rancher – First Reported Case

Sin Nee Tan¹, Thiam Seong Christopher Lim²

¹ Department of Medicine, Hospital Tengku Ampuan Afzan, Jalan Tanah Putih, 25100 Kuantan, Malaysia

² Nephrology Unit, Department of Medicine, Faculty of Medicine and Health Science, Universiti Putra Malaysia, 43400 Serdang, Selangor, Malaysia

ABSTRACT

Cryptococcal meningitis is a central nervous system infection caused by *Cryptococcus neoformans*. Although *Cryptococcus* is found in bird droppings, it has never been reported for those ranchers involved in the niche swiftlet ranching industry despite having close proximity with the bird droppings. We present here a case of a 41-year-old healthy swiftlet rancher who presents with a history of prolonged fever, headache and altered behaviour of a month duration. Cerebral spinal fluid analysis revealed the presence of *Cryptococcus*. He was treated with intravenous amphotericin B and flucytosine and discharged well with fluconazole consolidation therapy for 8 weeks, followed by maintenance therapy for 1 year. We believe this is the first reported case of *Cryptococcal* meningitis (CM) occurring in an immunocompetent swiftlet rancher. This case should highlight the needs to wear a proper personal protective equipment inside a swiftlet ranch due to the constant exposure to the potential *cryptococcal*-rich environment. A high index of suspicion, careful history taking and physical examination focusing on neurologic assessment is key to early diagnosis and timely management of CM.

Keywords: *Cryptococcus meningitis*, Immunocompetent, Swiftlet farmer, Amphotericin B

Corresponding Author:

Christopher Lim, FRCP

Tel: +603-89472568

E-mail: drchrislim@gmail.com

INTRODUCTION

Cryptococcus neoformans is an encapsulated yeast-like fungus that has a worldwide distribution. In 1950s, there were less than 300 reported cases but nowadays it was estimated that there are more than a million cases of *cryptococcal* infections worldwide. *Cryptococcus* has been recently classified into seven different species (1). The two most prominent species were *C. neoformans* and *C. gattii*. *C. neoformans* is found in soil contaminated with bird droppings and affects immunocompromised hosts with a typical background history of prolonged steroid usage, hematologic malignancies, solid-organ transplantation, diabetes mellitus, or human immunodeficiency virus (HIV) infection while *C. gattii* was found in eucalyptus trees in tropical or subtropical regions, which usually cause infection in the immunocompetent hosts.

CASE REPORT

Mr N, 41-year-old man with no known co-morbidities presented with intermittent fever, frontal headache, and altered behaviour for one-month duration. There were

no constitutional or raised intracranial pressure (ICP) symptoms. He was initially diagnosed as having sinusitis after a computed tomography (CT) scan of the brain revealed evidence of sinusitis with no other abnormality detected. However, his symptoms did not subside with the prescribed treatment and he sought medical advice again after 3 weeks has lapsed. On further probing, he was found to be a full-time swiftlet rancher who frequently visits swiftlet ranches for harvesting edible bird nests and cleaning the bird droppings. Upon his second admission, he was appeared to be confused with no other neurological signs documented. Systemic examination was unremarkable.

His initial full blood count was within normal limits. Full blood picture revealed neutrophillia with no abnormal cells seen. Serum creatinine level and liver function test were normal. Fasting blood sugar was 5.6 and he was not known to have diabetes mellitus. Urinalysis result was normal. HIV, treponema antibodies, hepatitis C virus antibody and hepatitis B surface antigen were not reactive. Serology for *Mycoplasma pneumoniae*, *Salmonella paratyphi*, *Salmonella typhi*, *rickettsial antibodies OX 19* and *OXK*, Dengue virus NS 1 antigen were all negatives. Blood and urine culture and sensitivities have no significant growth. However, his erythrocyte sedimentation rate was noted to be elevated at 33 mm/h. C-reactive protein was 1.5mg/L. Chest X-ray was reported as normal. Lumbar puncture (LP)

was performed and cerebral spinal fluid analysis (CSF) showed the presence of red blood cell at 175/uL (likely due to traumatic tap), low glucose level, high protein level (Table 1) with *Cryptococcus* seen in India ink staining (Figure 1). Opening pressure of CSF was not documented. No CSF fungal culture or cryptococcal antigen titre was sent due to the lack of laboratory facility at the referring hospital. His confusion state resolved immediately after LP. A diagnosis of *cryptococcal meningitis* (CM) was made and he was started on intravenous amphotericin B deoxycholate (AmBd) and flucytosin therapy. Patient was then referred to our centre for continuation of treatment due to financial constraint.

Upon presentation to our centre, he was orientated to time, place and person. Neurological and fundoscopy examination were unremarkable. Patient was treated with IV Amphotericin B 50mg OD (0.7mg/kg/day) and tablet Flucytosine 1500mg QID (100 mg/kg/day in 4 divided doses). He was to complete IV Amphotericin B plus flucytosine for total of 2 weeks duration followed by consolidate therapy with fluconazole 400mg BD for 8 weeks duration and maintenance therapy with fluconazole 200mg OD for another 6-12 months. A repeated LP on day 7 of treatment revealed clearing of the CSF (Table I). However, two months later, the patient was readmitted with severe frontal headache for a week duration. No neurological deficit was identified. Repeated contrasted CT scan of the brain was normal and a third LP was performed (Table I). Cryptococcal antigen latex agglutination titre (*Cryptococcus* Antigen Latex Agglutination Test System, IMMY) in CSF was 1:8, indicating a high likelihood of satisfactory response with the prescribed antifungal treatment. Patient remained well during clinic review and switched to maintenance therapy for one-year duration.

DISCUSSION

C.neoformans is the commonest cause of fungal meningitis worldwide and 4th most common

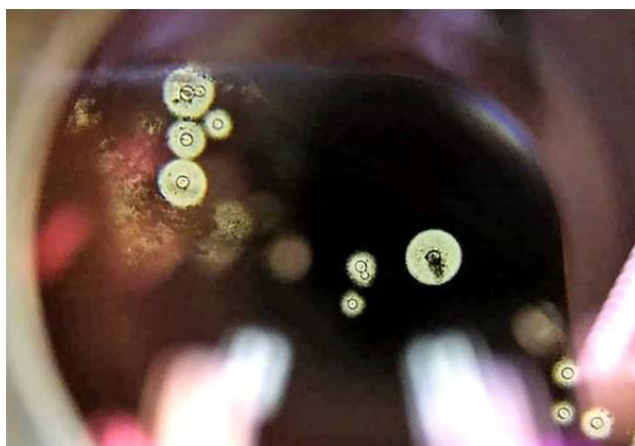


Figure 1 : Cryptococcus seen in India Ink stain

opportunistic infection in patients with HIV. It typically infects immunocompromised patients. CM is easily diagnosed by LP and CSF analysis including cell counts, biochemistry, protein, glucose, Indian ink staining (75-85% sensitive), fungal culture or *cryptococcal* latex agglutination assay (95% sensitive). Serum *cryptococcal* latex agglutination test has 87% sensitive in HIV-negative patients (2). CT or magnetic resonance imaging of the brain is mandatory prior to LP procedure to exclude the presence of hydrocephalus as this can be a sign of increase ICP. Typically, CSF analysis will reveal low glucose and high protein levels, a finding similar to ours (3). Although *Cryptococcus* antigen titre was not sent initially, a repeated LP revealed a titre of 1:8 which may imply that the patient is responding satisfactory to the prescribed treatment. Unfortunately, the repeated CSF cultures were negative, a factor which may be attributed by insufficient CSF samplings or the samples may not have undergone the necessary centrifugation process to increase the yield rate. Furthermore, the cultures were not specifically cultured for fungus.

To date, there is very little known about the pathogenesis and natural progression of CM in an immunocompetent

Table I: Serial CSF findings

CSF finding	30/8/17	8/9/17	17/10/17
Appearance	Clear	Clear	Clear
RBC/uL	175	0	0
WBC (<10 cells/iu)	0	10 (neutrophil)	30 (lymphocytes)
Protein (0.1-0.45)g/L	2.45	2.74	1.95
Glucose (2.2-4.2) mmol/l	0.2	0.4	1.1
Indian ink	Cryptococcus seen	Negative	Negative
Gram stained smear	No bacteria	No bacteria	No bacteria
Acid fast bacilli (AFB) smear	No AFB	No AFB	No AFB
Globulin	Positive	Negative	Positive
Culture	No growth	No growth	No growth
Opening pressure	-	18cmH ₂ O	5cm H ₂ O

host. It is important to rule out undiagnosed diabetes in CM as hyperglycemia can impair host defence mechanism. Our patient is fit swiftlet rancher who has frequent exposure to bird droppings. His initial presentation of fever and headache with negative neurological findings has not prompted the diagnosis of CM as CM has not been reported those working in the swiftlet ranching before. In our case report, we are unable to prove that CM was directly cause by exposing to *cryptococcal*-rich work environment as fungal culture of the workplace was not performed. Nevertheless, harmless fungal contamination with *Aspergillus* sp., *Candida* sp., *Cladosporium* sp., *Neurospora* sp., and *Penicillium* sp. is known to be present in raw cleaned edible bird nest (EBN). Swiftlets, the birds that produce EBN are non-migratory and do not share flying or nesting space with other species of birds. Hence their chance of contracting the avian virus is minimal (4). Transmission of *Cryptococcus* infection from swiftlets to human has not been documented despite the close human encounters to the human kinds.

Many swiftlet ranchers manage the farm without proper personal protective equipment that could protect them from fungal or bacterial infections. We postulate that chronic exposure to *cryptococcal*-rich environment could predispose a healthy person to acquire cryptococcal infection but further study need to be perform to confirm the actual presence of *cryptococcus* inside the swiftlet ranches.

Combination of amphotericin B deoxycholate plus flucytosine is the most effective fungicidal regimen in *cryptococcal* infection. CSF *Cryptococci* clearance was significantly faster with amphotericin B deoxycholate and flucytosine combination comparing with amphotericin B deoxycholate alone, amphotericin B deoxycholate plus fluconazole, and triple-drug therapy. Hence, current induction therapy for CM in non-HIV infected and non-transplant patient is amphotericin B deoxycholate (0.7–1.0 mg/kg/day) plus flucytosine (100 mg/kg/day) for 4weeks, which may be extended to 6weeks if neurological complications are present. Unfortunately, there is no clear treatment consensus for length of induction therapy in immunocompetent group of patients with *cryptococcal* infection (5).

There is limitation of our case report. Firstly, we are not able to confirm the presence of *cryptococcus* inside a swiftlet ranch as the permission to take samples was not granted.

CONCLUSION

CM is a rare disease in immunocompetent patients. We believe this is the first reported case of CM occurring in a healthy swiftlet rancher. This case should highlight the needs to wear proper personal protective equipment inside a swiftlet ranch due to the constant exposure to the potential *cryptococcal*-rich environment. However, more studies need to be carried out to study the presence of *Cryptococcus* in work environment and to ascertain its direct relationship. A careful history and physical examination focusing on neurologic assessment with a high index of suspicion in patients with known exposure is key to early diagnosis and timely management of CM.

ACKNOWLEDGEMENT

Dr Teh Hoi Poh for the Indian Ink stained picture

REFERENCES

1. Hagen F, Khayhan K, Theelen B, Kolecka A, Polachek I, Sionov E, et al. Recognition of seven species in the *Cryptococcus gattii*/*Cryptococcus neoformans* species complex. *Fungal genetics and biology* 2015; 78: 16-48.
2. Yanes BB, Hanna GM, Juliana FS, Fernanda S, Gilberto MJ, Sergio DJ, et al. Cryptococcal Meningitis in immunocompetent patient-case report. *American Medical Journal* 2013; 4 (1): 100-104.
3. Bicanic T, Harrison TS. Cryptococcal meningitis. *Br Med Bull* 2005; 72: 99–118.
4. Lim,C. 2006. Make Millions from Swiftlet Farming: A Definitive Guide. TrueWealth Sdn Bhd.,Malaysia
5. Perfect JR, Dismukes WE, Dromer F, Goldman DL, Graybill JR, Hamill RJ, et al. Clinical practice guidelines for the management of cryptococcal disease: 2010 update by the Infectious Diseases Society of America. *Clin Infect Dis* 2010;50:291–322.