

## CASE REPORT

# Retinoblastoma in an Older Child: A Case Report

Ong Wu Zhuan<sup>1,3</sup>, Jamalia Rahmat<sup>2</sup>, Sunder Ramasamy<sup>2</sup>, Amir Samsudin<sup>3</sup>

<sup>1</sup> Department of Ophthalmology, Hospital Selayang, Lebuhraya Selayang-Kepong, 68100 Batu Caves, Selangor Darul Ehsan, Malaysia

<sup>2</sup> Department of Ophthalmology, Hospital Kuala Lumpur, Jalan Pahang, 50586 Kuala Lumpur, Malaysia

<sup>3</sup> Department of Ophthalmology, Faculty of Medicine, University of Malaya, 50603 Kuala Lumpur, Malaysia

### ABSTRACT

Retinoblastoma is a rare intraocular malignant tumour more commonly seen in children below five years of age. We presented a rare case of retinoblastoma in an older child. A nine-year-old girl noticed that she had loss of vision OS following a fall at home. Her vision was 6/6 OD and only light perception OS. Examination of the left eye revealed an extensive exudative retinal detachment. Her right eye examination was unremarkable. CT scan showed a left eye intraocular mass with calcification. EUA revealed a mixed endophytic and exophytic mass with extensive exudative retinal detachment. Family members consented to left eye enucleation and histopathological report confirmed the diagnosis of retinoblastoma. Post enucleation, patient is doing well with a prosthetic eye. In conclusion, any unexplained visual loss in children regardless of age warrants a full ophthalmological examination as the possibility of retinoblastoma cannot be ruled out.

**Keywords:** Retinoblastoma, Exudative retinal detachment

### Corresponding Author

Dr Ong Wu Zhuan

Tel : +603 61263333 Ext 6017

Fax : +603 6137 7097

Email: owz86@yahoo.com

### INTRODUCTION

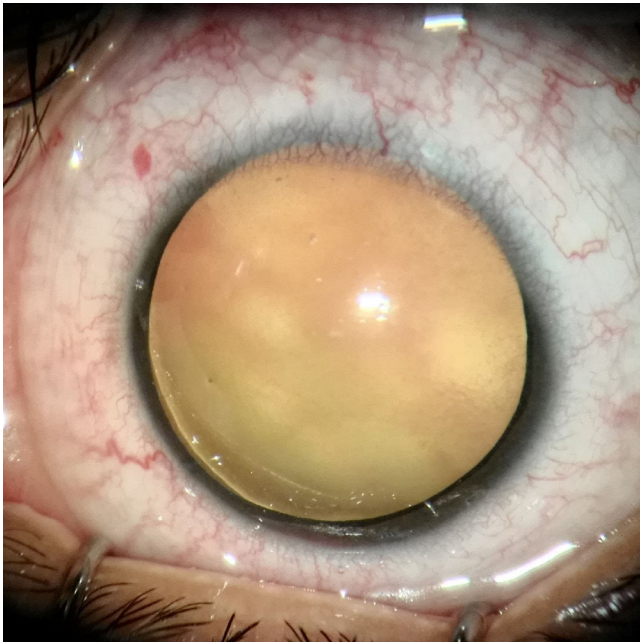
Retinoblastoma is rare, but it remains the most common primary intraocular malignant tumour in the paediatric group. It typically affects children less than five years of age. Leukocoria and strabismus are the two most common presentations in younger children, usually noticed by the parents. We discuss a case of atypical presentation of retinoblastoma in an older child and the challenges in the management.

### CASE REPORT

A nine-year-old girl, who was previously fit and well, was brought to the hospital by the caretaker following a fall at home. Her left eye accidentally hit the edge of the table during the incident. She claimed she was unable to see with that eye following the fall. Otherwise, she denied any eye pain or redness, and there was no significant family history of carcinoma. She was seen by the primary doctor and referred to the tertiary hospital for further investigations and management.

At presentation, her vision was 6/6 OD and only light perception OS. On examination, the left eye cornea was clear, and the anterior chamber was deep. There was presence of microhyphaema in the anterior chamber. The pupil was fixed and dilated with 360 degrees of ectropion uvea (Fig. 1). The lens was normal, and fundus examination revealed an extensive exudative retinal detachment. Her right eye examination was unremarkable. B-scan showed an open funnel retinal detachment with a subretinal hyperechoic lesion. CT scan orbit (Fig. 2) showed a left eye intraocular mass with hyperdense lesion suggestive of calcification.

She was posted for examination under anaesthesia (EUA), which revealed a mixed endophytic and exophytic mass at the nasal retina with overlying tortuous vessels and extensive exudative retinal detachment (Fig. 3). There were multiple subretinal deposits at the macula. The provisional diagnosis was retinoblastoma versus advanced Coats' disease. Family members were counselled regarding the possibilities of these two conditions and the option of enucleation was discussed thoroughly with them. They consented to the surgery and left eye enucleation was performed. During the surgery, the optic nerve was sectioned as far as 11mm behind the globe. Medpore orbital implant was inserted at the same setting and a prosthetic eye was fitted six weeks later.



**Fig. 1.** Ectropion uvea with fixed dilated pupil

Histopathological examination confirmed the diagnosis of intraocular retinoblastoma. There was pre-laminar optic nerve invasion with focal choroidal invasion, however there was no intrascleral invasion (Fig. 4). She was also co-managed with a paediatric oncologist. As there was no systemic involvement, and with the tumour confined intraocularly, no chemotherapy was warranted for her. Post enucleation, she is doing well with a prosthetic eye with no recurrence.

## DISCUSSION

Retinoblastoma remains a rare tumour in children, despite being the most common primary intraocular tumour in paediatric age group. It has an estimated incidence of one in 20,000 live births worldwide (1). It is more commonly seen in early childhood, and up to 95% of cases are diagnosed before the age of five years. In a retrospective study done by Chang et al, only 3.9% of retinoblastoma was found in children above 5 years old. Out of the 1205 patients, less than 1% of cases occurred in the age group of 7 to 14 years (2). The average age of diagnosis for bilateral and unilateral retinoblastoma is before twelve months and twenty-four months respectively (1).

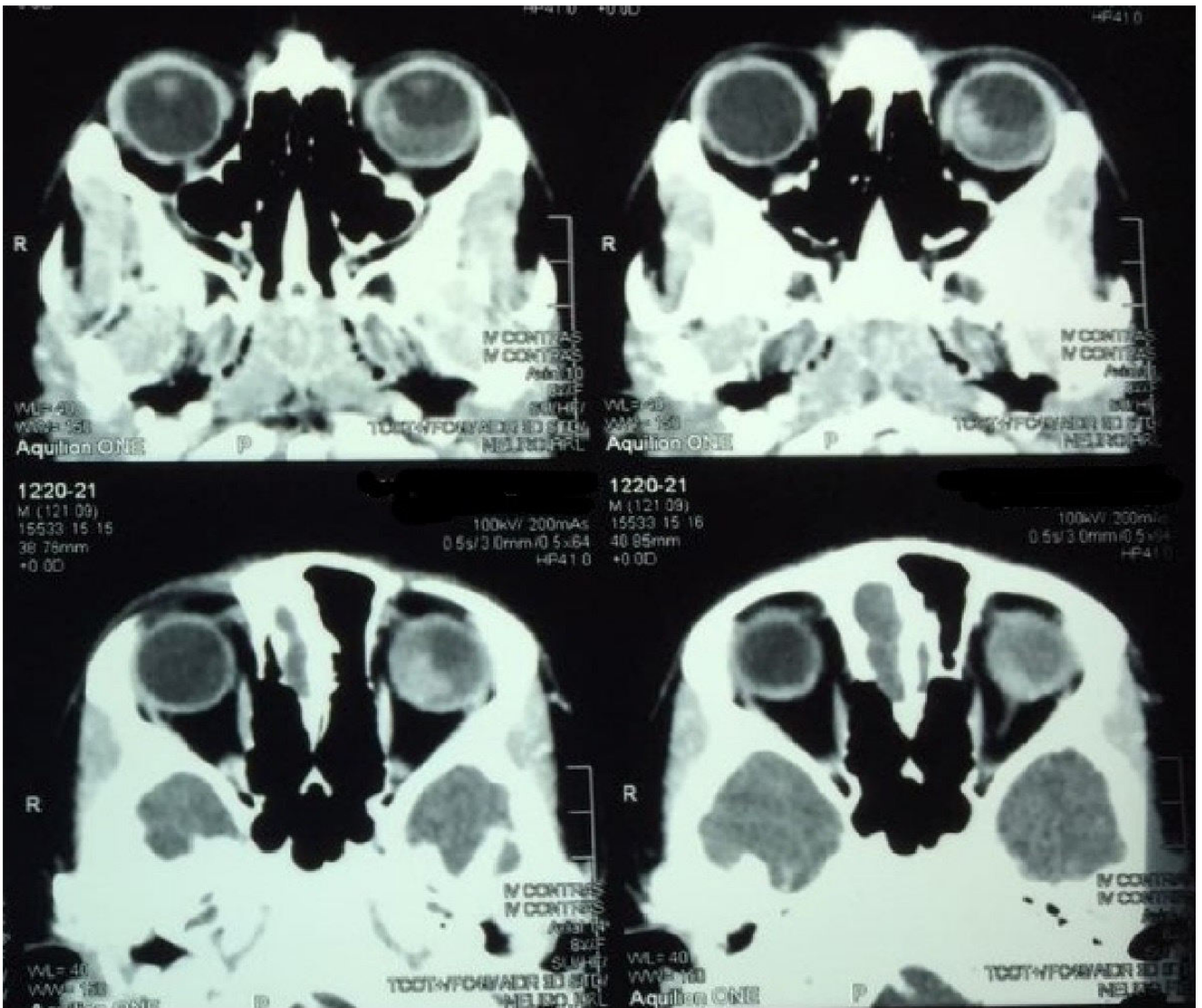
The pathogenesis of retinoblastoma can be explained by Knudson's 'two-hit' hypothesis, that two separate mutations on RB1 tumour suppressor gene are responsible for the carcinogenesis of retinoblastoma. 40% of cases are hereditary and the remaining 60% are non-hereditary (3). In hereditary retinoblastoma, one mutation is inherited

through the germ line and subsequent somatic mutation will result in bilateral or multifocal retinoblastoma. On the other hand, non-hereditary retinoblastoma requires two separate mutation in the somatic cells and often results in unilateral retinoblastoma (3). Retinoblastoma is a malignant tumour of immature retinal cells or retinoblasts. This 'two-hit' oncogenic mutation occurs between third month post-conception and the age of four years, the period of time when the development and final maturation of retinoblasts occur. This explains why retinoblastoma is almost exclusively found in children younger than 5 years old (4).

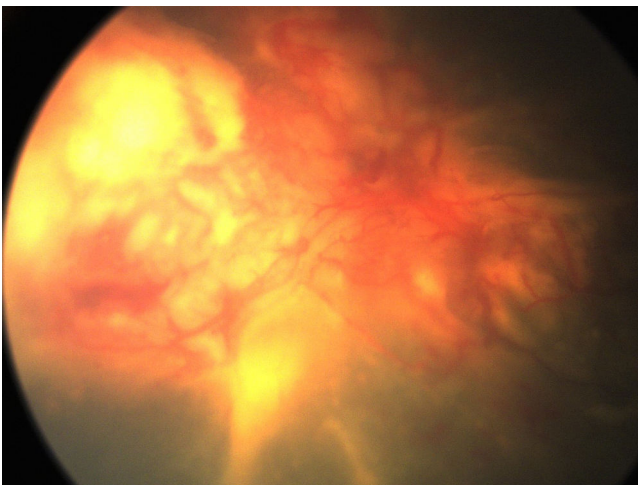
The age of presentation of our case is nine years old, which is way above the average age. However, no genetic study was done in this case to further confirm the genetic correlation. The reasons for the late presentation of retinoblastoma in children above five years old remain unclear and are debatable. Previously, it is postulated that late onset retinoblastoma may be due to the persistence of embryonal retinoblasts, or the tumour may have arisen from the reactivation of a previously spontaneously arrested tumour. Later studies also discovered more complex genetic abnormalities in retinoblastoma from older children as compared to that from younger age group (2). Hopefully, with the advancement in genetic studies in future, we can understand the pathogenesis of late onset retinoblastoma better.

The clinical presentations of retinoblastoma in older children might differ from that seen in younger children. Leukocoria and strabismus are the common presentation of retinoblastoma in children, but older children can also present atypically with decreased vision, eye pain, photophobia and lacrimation (2). The atypical symptoms are mainly attributed to the ability of older children to express their complaints. In this case, it was the child who first noticed the loss of vision in her left eye, thus leading to further eye examination. Late onset retinoblastoma causes diagnostic dilemma owing to its rarity and presence of other mimicking conditions. This may contribute to delayed diagnosis or misdiagnosis, consequently increasing the risks of extraocular spread and lead to a higher risk of mortality. Other uncommon but possible presentations include uveitis, vitreous opacity, vitreous haemorrhage, retinal detachment, orbital inflammation, or neovascular glaucoma (1,2).

Coats' disease is one of the most common misdiagnosis and it remains a great challenge for ophthalmologists to differentiate between retinoblastoma and Coats' disease sometimes. Both retinoblastoma and advanced Coats' disease may present with combination of retinal detachment, abnormal retinal vasculature and subretinal mass (5), as illustrated in this case. Confusion is even more if the age at presentation is atypical. Improved diagnostic techniques such as computed tomography (CT) and magnetic resonance imaging



**Fig. 2.** CT scan with contrast (Axial cut) showing intraocular enhancing mass with calcification in the left eye



**Fig. 3.** Mixed endophytic and exophytic growth with exudative retinal detachment. Angry looking feeder vessels overlying the mass



**Fig. 4.** (X20 magnification) with Haematoxylin and Eosin stain. Tumour cells confined intraocularly without retrolaminar optic nerve invasion.



(MRI) certainly help in the diagnosis of these conditions. Although exophytic retinoblastoma typically presents with radiological evidence of calcification, up to five percent of retinoblastoma may not show evidence of calcification. On the other hand, Coats' disease commonly presents without calcification, yet there are cases of Coats' disease with evidence calcification being reported (5).

When there is uncertainty in diagnosis, the clinicians need to weight the benefits of enucleation against the risks without enucleation. Certainly, enucleation of one eye will cause significant psychological and social impact on the affected children. However, failure to diagnose and treat retinoblastoma may lead to significant morbidity and even mortality to the patients. It is still safer to offer enucleation when there is diagnosis uncertainty and retinoblastoma is suspected.

## CONCLUSION

Retinoblastoma is a treatable condition and should be managed in a holistic approach. Even though retinoblastoma is more commonly seen in younger children, it can still occur in older children. Any unexplained visual loss in children regardless of age warrants a prompt ophthalmology referral and proper eye examination.

## ACKNOWLEDGEMENT

The authors would like to thank the Director General of Health Malaysia for his permission to publish this article. We would also like to thank Department of Pathology, Hospital Kuala Lumpur for the histopathology images and interpretation.

## REFERENCES

1. Cassoux N, Lumbroso L, Levy-Gabriel C, Aerts I, Doz F, Desjardins L. Retinoblastoma: Update on Current Management. *Asia-Pacific journal of ophthalmology (Philadelphia,Pa.)*.2017;6(3):290.
2. Chang Y, Shi J, Zhao J, Xu X, Ma J, Shen L, et al. Retinoblastoma in Chinese Children Aged Five to Fourteen Years. *Ophthalmologica*. 2015;233(3-4):222-9.
3. Leiderman YI, Kiss S, Mukai S. Molecular Genetics of RB1-The Retinoblastoma Gene. *Seminars in ophthalmology* 2007 Jan 1;22(4):247-254.
4. Balmer A, Zografos L, Munier F. Diagnosis and current management of retinoblastoma. *Oncogene*. 2006 Aug;25(38):5341.
5. Steidl SM, Hirose T, Sang D, Hartnett E. Difficulties in excluding the diagnosis of retinoblastoma in cases of advanced Coats' disease: a clinicopathologic report. *Ophthalmologica*. 1996;210(6):336-40.