

## CASE REPORT

# Isolated Complete Popliteus Tendon Rupture Following a Trivial Occupational Injury

Arifaizad Abdullah<sup>2</sup>, Mohd Hezery Harun<sup>2</sup>, Hariati Jamil<sup>3</sup>, \*Ezamin Abdul Rahim<sup>1</sup>

1 Department of Imaging, Faculty of Medicine and Health Sciences, Universiti Putra Malaysia, 43400 Serdang, Selangor, Malaysia

2 Department of Orthopaedic, Faculty of Medicine and Health Sciences, Universiti Putra Malaysia, 43400 Serdang, Selangor, Malaysia

3 Putrajaya Hospital, Jalan P9, Pusat Pentadbiran Kerajaan Persekutuan Presint 7, 62250 Putrajaya, Malaysia

### ABSTRACT

Traumatic rupture of the popliteus tendon is a rare type of knee injury. Most reported cases had occurred in athletes or following high impact trauma. We report a case of a 23-year-old male with an isolated complete popliteus tendon rupture that was diagnosed arthroscopically. The patient worked as a general labourer in a sawmill. He fell at his workplace and presented with acute painful fixed flexion of the right knee. Initially he was suspected to have a meniscus tear. Diagnostic arthroscopy of the knee was carried out; and diagnosis of popliteal tendon rupture was established. The patient was subsequently managed conservatively by arthroscopic debridement. He was allowed to mobilize the knee as tolerated after the surgery. He was well with a full knee range of movement and was able to walk normally at six weeks after surgery. This article highlights the possibility of complete popliteus tendon rupture following a minor occupational injury in a previously normal knee.

**Keywords:** Tendon injuries, Rupture, Occupational injuries

### Corresponding Author:

Dr. Ezamin Abdul Rahim

Tel: +60196846933

Email: [drezahar@gmail.com](mailto:drezahar@gmail.com)

The load that he carried was not more than 10 kilograms. He was not able to recall any twisting force or excessive external force to the knee during the injury. The pain persisted after the fall, especially during bending and straightening the knee. He has no known knee injury.

### INTRODUCTION

Popliteus tendon rupture is a rare condition with no obvious real incidence (1-3). It is most often associated with injuries of other structure such as meniscus and other knee ligaments (4). Brown et al. (1995) suggested that the incidence of purely isolated popliteus tendon injury is about 8.3% (4). We report a case of complete popliteus tendon rupture in a 23-year-old man who presented with acute painful fixed flexion of the right knee following a fall at his workplace. The injury was diagnosed by knee arthroscopy and supported with post-arthroscopic MRI findings.

Upon examination of the patient, the right knee was held in a 90 degrees flexion position. The knee was swollen with no obvious bruises or wound. There was tenderness at posterior aspect of the lateral joint line. The passive range of motion of the knee was merely from 90 degrees to 110 degrees flexion. Severe pain was elicited while attempting to straighten the knee. Laxity test could not be performed due to unbearable pain.

### CASE PRESENTATION

A 23-year-old man presented to the emergency department at a local hospital after a fall while working in a warehouse. He was a labourer employed in a sawmill. While carrying a pile of wood, he suddenly tripped and fell with both his knees hitting the ground.

Standard AP and lateral right knee X-ray showed no obvious fracture or dislocation. The patient was admitted for rest, affected limb elevation and pain relief. The pain did not improve despite optimum medical therapy. Right knee arthroscopy was carried out three days after the injury. The arthroscopy finding revealed an empty lateral hiatus that suggested a complete popliteal tendon rupture. There was a blood clot seen within the hiatus. Other structures such as the meniscus and the ligaments, especially lateral collateral ligament and posterior cruciate ligament, were all grossly intact. Debridement and lavage were performed and, subsequently, the knee managed to be straightened

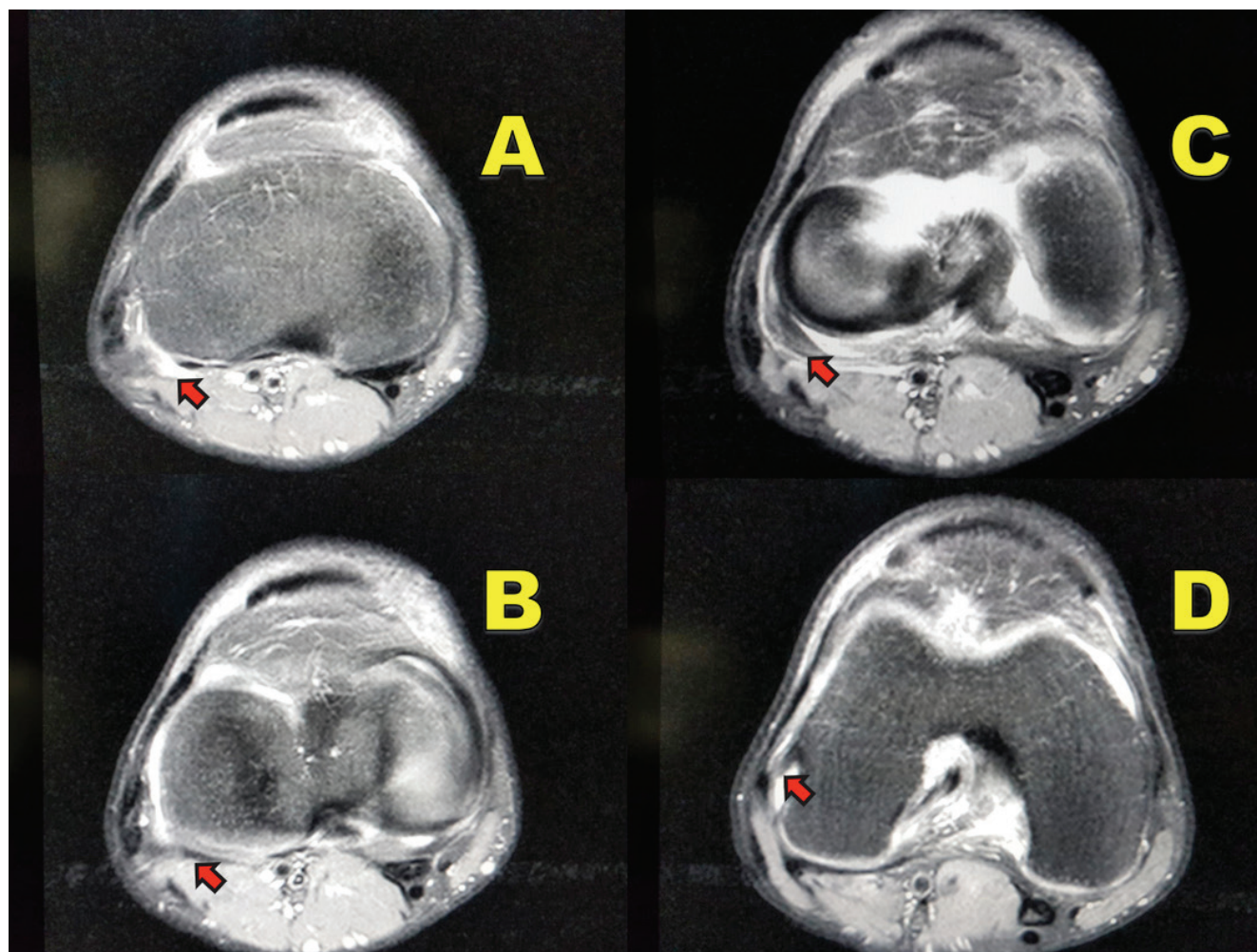
during the surgery. Magnetic resonance imaging (MRI) was done 2 weeks post-surgery with the intention to exclude any associated extra-articular structure injuries. The lapsed period between post-surgery to MRI was to allow any fluid from the surgery to be absorbed by the body (Fig. 1). The immediate post-operative period was uneventful. During the initial follow-up, there was a great improvement of the range of motion within 2 weeks post-surgery. A complete recovery with full range knee movement was seen after 6 weeks post-surgery. At three months post trauma; there was complete range of motion of the above said knee. He had defaulted follow up at 9 months post trauma.

## DISCUSSION

The popliteus muscle is a small muscle located at the posterior aspect of the knee. It originates from the

posteromedial surface of the proximal tibia and inserted into the lateral femoral condyle proximally. The main function of this muscle is for the inward movement of the tibia in the non-weight bearing state and external rotation of the femur when weight-bearing. The popliteus muscle plays an important role to unlock the knee from full extension and maintain posterior stability of the knee. It is one the main lateral stabilizers to the knee (2).

Most of the reported cases of popliteus tendon rupture occurred mainly among athletes (1, 2). The exact mechanism of injury was unknown, popular postulations suggested that isolated popliteus tendon injuries happened when a force was directed against the knee joint medially with the knee at full extension or near full extension, which in turn caused strain to the postero-lateral structures. There were other mechanisms of injuries described in previously reported cases (1-3). The presentation of the patient with this kind of



**Fig. 1** Serial axial PD MRI image showing the course of the popliteus tendon in the patient. A- The arrowhead shows the tendon near its muscle portion. Note the presence of fluid surrounding the popliteus tendon. B- The arrowhead indicates the popliteus tendon to be thinned out adjacent to the ruptured tendon. C- The arrowhead in the image C is showing a "gap" with a complex structure suggestive of a popliteus tendon stump. D- The arrowhead shows the intact popliteus tendon attachment to the lateral femoral condyle. Note the presence of fluid surrounding the tendon

injury varies. It Patient could be presented with mild to moderate discomfort at the posterolateral site of the knee or, in contrast, the patient could be presented with severe knee pain and haemarthrosis (1).

In the case reported here, the injury occurred to a labourer, not an athlete. The mechanism of injury was a fall in a kneeling position with both knees hitting the floor was different from other previously reported cases. The mechanism of the popliteus tendon injury in this patient was poorly understood. There was no finding detected via the arthroscopy or MRI to suggest degenerative disease or specific tendon overuse. The presentation of the patient was also uncommon. He was presented to our Emergency Department with the injured knee was at 90-degree flexion and was extremely painful. We initially thought he had a bucket-handle meniscus injury rather than popliteal tendon injury due to the abovementioned reason.

The diagnosis was confirmed via arthroscopy (2). The arthroscopic examination showed a clear-cut intra-articular isolated complete tear of the popliteus tendon. The advantages of early arthroscopy as an examination tool were; apart from it being a confirmatory examination, arthroscopy also provided an opportunity for debridement procedure in the same setting. The treatment of isolated popliteal tendon rupture is remained controversial. Reports suggested that conservative treatment with arthroscopic debridement produced a good result (1,2,3). In our case, the patient was successfully treated with arthroscopic debridement and lavage. A complete recovery is expected in most of the patients. (1,2,3). There was no residual instability or recurrent painful flexed knee experienced by the patient.

## CONCLUSION

We wanted to highlight that even a minor fall in a kneeling position could produce this rare form of injury. It should be one of the differential diagnoses when a patient presented with knee pain in a fixed flexion at 90 degree especially when the diagnostic arthroscopy revealed that the meniscus and ligament are intact.

## ACKNOWLEDGEMENT

This article was supported by research grants from Universiti Putra Malaysia GP-IPM (Project No: GP-IPM/2014/9438300). We would like to thank the Department of Radiology Universiti Putra Malaysia, Department of Orthopaedic Universiti Putra Malaysia and Hospital Serdang for their support of this article.

## REFERENCES

1. Mariani PP, Margheritini F. Partial isolated rupture of the popliteus tendon in a professional soccer player: A case report. *Sports Med Arthrosc Rehabil Ther Technol.* 2009;1:18.
2. Guha AR, Gorgees KA, Walker DI. Popliteus tendon rupture: A case report and review of the literature. *Br J Sports Med.* 2003;37:358-360.
3. Burstein DB, Fisher DA. Case report: Isolated avulsion of the popliteus tendon in a professional athlete. *Arthroscopy.* 1990;6:238-41.
4. Brown TR, Quinn SF, Wensel JP, Kim JH, Demlow T. Diagnosis of popliteus injuries with MR imaging. *Skeletal Radiol.* 1995;24(7):511-4.