

CASE REPORT

Radical Resection of Primary Leiomyosarcoma of Inferior Vena Cava

Ikhwan Sani Mohamad¹, Sivabalan Nadarajan², Zamri Zuhdi², Azim Idris³, Hairol Othman², Affirul Chairil⁴, Razman Jarmin²

1 Department of Surgery, School of Medical Sciences, Universiti Sains Malaysia, 16150 Kota Bharu, Kelantan, Malaysia

2 Hepatopancreaticobiliary Unit, Department of Surgery, Faculty of Medicine, Universiti Kebangsaan Malaysia, Jalan Yaacob Latif, Bandar Tun Razak, 56000 Cheras, Kuala Lumpur, Malaysia

3 Vascular Unit, Department of Surgery, Faculty of Medicine, Universiti Kebangsaan Malaysia, Jalan Yaacob Latif, Bandar Tun Razak, 56000 Cheras, Kuala Lumpur, Malaysia

4 Department of Surgery, Faculty of Medicine and Health Sciences, Universiti Sains Islam Malaysia, Jalan Pandan Utama, Pandan Indah, 55100 Kuala Lumpur Malaysia

ABSTRACT

Leiomyosarcoma of the Inferior Vena Cava (IVC) is a rare soft tissue tumour which accounts for only 0.5% of all soft tissue sarcomas. The patients usually presented with non specific clinical signs and often diagnosed at advanced stage. We reported a case of a 58-year-old lady who presented with right sided abdominal pain for 6 months. CT scan showed large Level 2 IVC tumour which encased the right renal vein and had no clear plane of demarcation with the caudate lobe of the liver. She underwent radical resection of the IVC tumour with the right kidney removed en bloc. Vascular reconstruction was not performed as established collateral veins present. She was nursed in Intensive Care Unit for 2 days and discharged well at day 5 post operatively. Histopathological examination results revealed leiomyosarcoma of IVC.

Keywords: Inferior vena cava leiomyosarcoma, Radical resection, IVC tumour

Corresponding Author:

Ikhwan Sani Mohamad

Tel: +60179278535

E-mail: ikhwansani@yahoo.com.my

INTRODUCTION

Leiomyosarcoma of IVC is a malignant tumour which arises from the wall of the vein. As the tumour arise from retroperitoneum, most of the patient presented with nonspecific symptoms thus usually diagnosed at advanced stage. It usually raises major concern to the surgeons as the location of the IVC makes the dissection challenging. Furthermore, reconstruction of IVC may results in major complications. Radical resection should be considered to achieve curative intent of management which possibly involving resection of tumour with right kidney and caudate lobe of liver with or without vascular reconstruction. These cases are usually referred to the specialized centre with available service of vascular surgeons and hepatobiliary surgeons for the best surgical outcomes.

CASE REPORT

A 58-year-old lady presented with history of right sided abdominal pain for 6 months. There was no history of abdominal distention, endocrine related symptoms, leg swelling, bowel related symptoms or family history of malignancy.

On examination, she looked comfortable with normal vital signs. Abdomen was soft with palpable firm mass at right hypochondrium measuring 8x10cm with irregular margin. No visible distended veins or pedal edema elicited.

The CT-Scan showed a heterogeneous enhancing retroperitoneal mass with central necrosis extending from the level of caudate lobe to right renal hilum (from T11 to L2 vertebral level) measuring 7.1x6.2x8.9cm.(Fig. 1) No calcification seen. This diagnosis of aggressive leiomyosarcoma arising from IVC was made as parts of the normal infrahepatic IVC not seen and seems to be inseparable from the tumour. No clear plane can be appreciated with the liver cranially as well as right renal artery and vein caudally.

Intraoperative finding was a large IVC lesion from the branch of renal veins to the proximal hepatic vein, with superior margin abutting caudate lobe of the liver.(Fig. 2) Tumour had to be mobilized with resection margin extending from 2cm inferior to hepatic vein till infra renal IVC. There was clear plane between tumour, liver and portal triad. Clamping of the suprahepatic IVC did not result in hypotension or decrease venous return throughout surgery. Invaded right and left renal vein left renal vein was divided and ligated. Right kidney was removed en bloc with tumour. Left renal vein was also ligated due to tumour encasement. Postoperatively patient was nursed in ICU and had an uneventful recovery with kidney function remain normal despite single left kidney and the left renal vein being ligated. She did not develop any pedal edema and was discharged well 5 days after the surgery.

Macroscopically, the tumour was described as Kieffer stage 2 (located between the renal veins and hepatic veins). The tumour size was 7 cm AP diameter x 6 cm width x 9 cm height craniocaudally and has no plane of demarcation with right kidney and adrenal gland. Cut section of the tumour show fleshy, yellowish tan mass with minimal areas of cystic change filled with blood. The inner vascular surface is smooth.

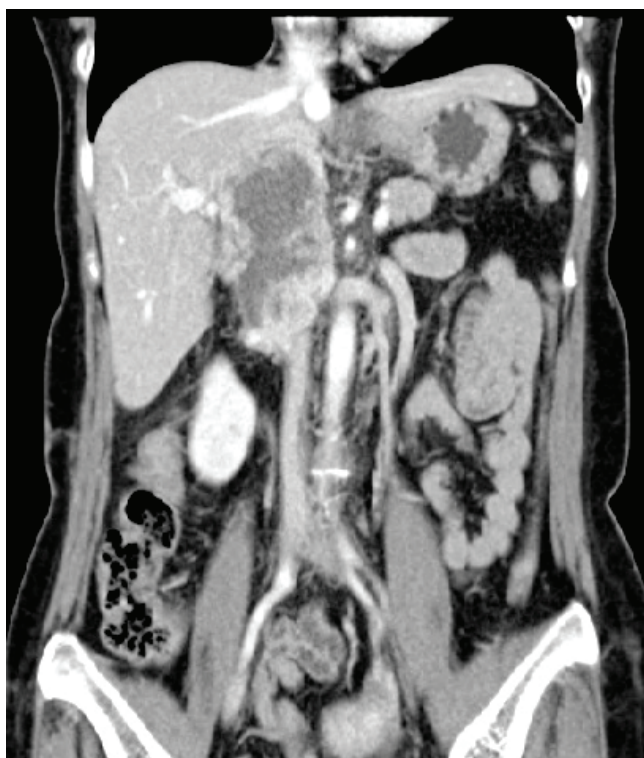

Fig. 1 Heterogenous enhancing retroperitoneal mass with central necrosis extending from the level of caudate lobe to right renal hilum (arrow). No clear plane can be appreciated with the liver cranially as well as right renal artery and vein caudally.

Histopathological microscopic examination revealed a cellular tumour arising from vessel wall composed of intersecting, marginated fascicles of spindle cells with occasional storiform arrangement. The tumour cells generally have hyperchromatic elongated, blunted-ended nuclei with eosinophilic cytoplasm (Fig. 3). At some areas, they are markedly pleomorphic with atypical indented and lobated nuclei (histologic type score 2). Mitotic figures are easily seen (8 mitoses/10HPF)(score 1). Foci of tumour necrosis (<50% of the tumour mass) (score 1), myxoid change and hyalinization are also present. No osteosarcomatous or rhabdosarcomatous component seen. The tumour is abutting the right kidney and right adrenal gland. No direct infiltration into their parenchyma.

Immunohistochemically, the neoplastic cells are positive for SMA and Desmin. Final histopathology was reported as leiomyosarcoma of large vessel (IVC) , histological grade 2 (FNCLCC -French Fédération Nationale des Centres de Lutte Contre le Cancer) grading system) , Stage T2b, N0, M0.

She was then referred to the oncologist for post operative follow up and completed 25 fractions of 50 Grays Radiotherapy.

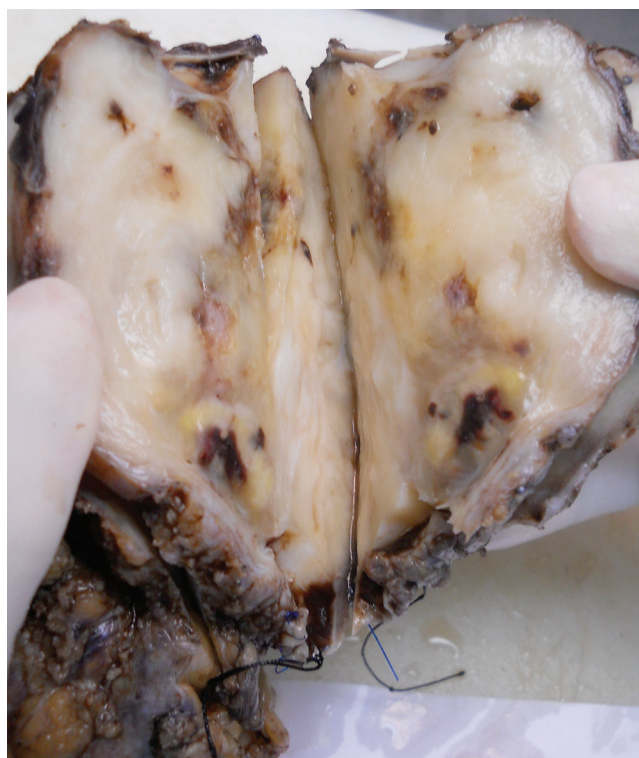


Fig. 2 Section of the tumour show fleshy, yellowish tan mass with minimal areas of cystic change filled with blood. No obvious vascular tracts seen within it. The inner vascular surface is smooth.

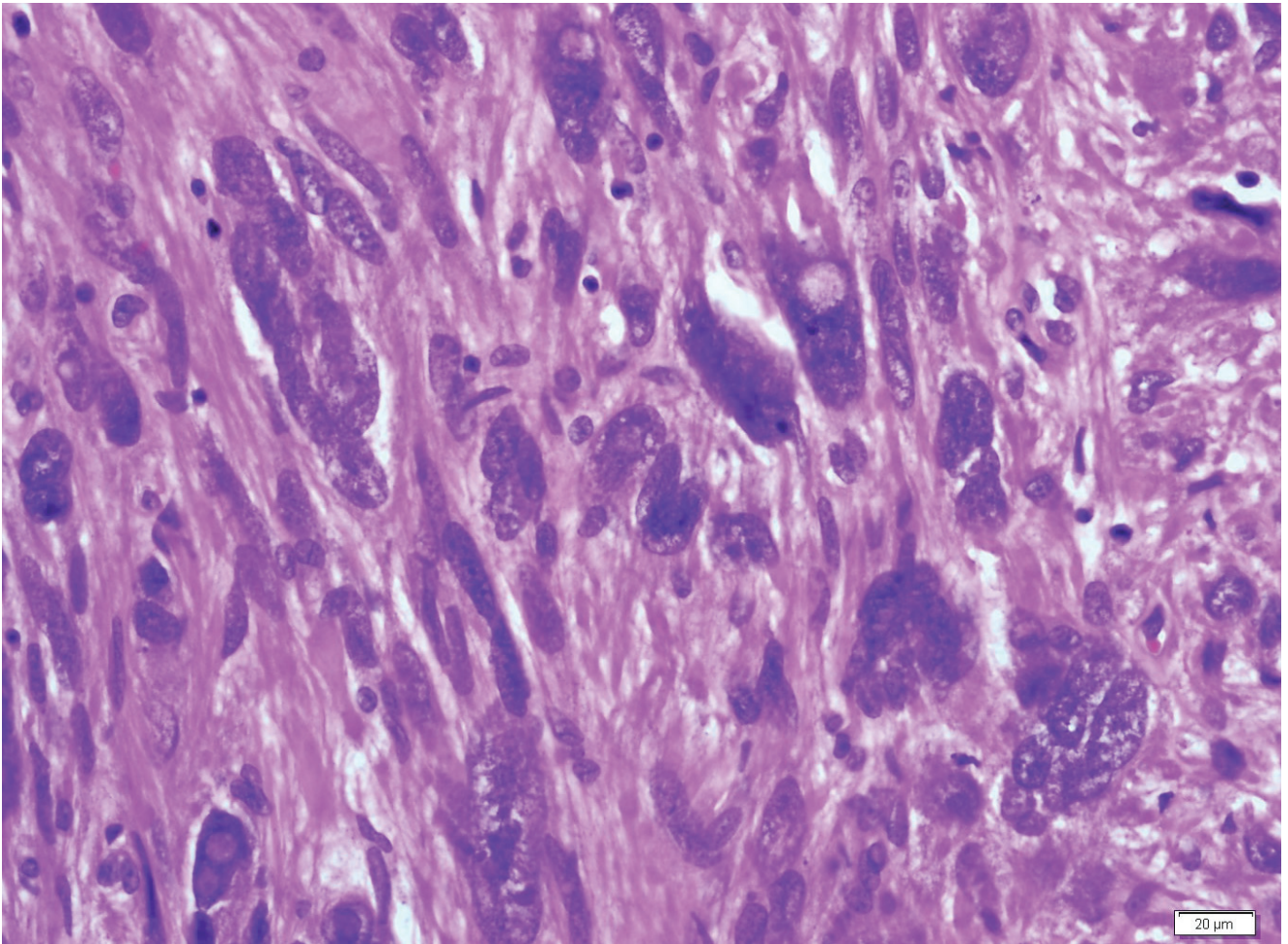


Fig. 3 Section shows a cellular tumour arising from vessel wall composed of intersecting, margined fascicles of spindle cells with occasional storiform arrangement. The tumour cells generally have hyperchromatic elongated, blunted-ended nuclei with eosinophilic cytoplasm.

DISCUSSION

Leiomyosarcoma of IVC is a very rare clinical conditions which accounts for only 0.5% of all soft tissue sarcomas¹. Since the first case described by Perl in 1871, only 218 cases of IVC leiomyosarcomas were reported after 100 years². The first documented large report was described by Jean Hardwigen in 2001 when he reported case series of 14 IVC tumours³. Since then, Kieffer et al (2006) and Hollenback et al (2003) reported 22 and 25 cases respectively⁴.

Leiomyosarcomas of IVC are classified based on its anatomical levels. Kieffer et al. described IVC tumour whether they are located between the entry of the hepatic veins to the right atrium (Level 1); between the confluences of the renal and hepatic veins (Level 2); or below the renal veins (Level 3). This patient presented with Level 2 IVC tumour⁵.

The mainstay treatment for this soft tissue sarcomas are still radical en bloc resection of the affected IVC with other involved adjacent structures. The goals of surgical

management of these tumors include the achievement of local tumor control, maintenance of caval flow, and the prevention of recurrence. There are few reported techniques in dealing with the IVC following excision including IVC ligation; primary repair of IVC; patching of IVC and interposition grafting with a synthetic conduit³.

Specific procedures and interventions vary based on few important factors, such as primary tumor location, extent of the primary tumor (tumour stage), and degree of malignancy (grade); and degree of infiltration or spread to regional lymph nodes or adjacent structures such as liver, kidney and adrenal gland.

However in this patient, aggressive resection without vascular reconstruction has been the treatment of choice as the long standing nature of the symptom without pedal edema and normal renal function pre operatively despite complete obstruction of the IVC. Presence of collaterals at the abdominal wall and retroperitoneal space in the CT-Scan support the decision for aggressive resection.

Vascular Reconstruction after the IVC resection is not mandatory as some of these tumours already formed established collaterals like this case due to gradual long standing occlusion or thrombosis⁵. As a general rule, pressure monitoring should be performed to rule out excessive venous hypertension during IVC clamping. Proximal pressure reading of 30 mm Hg or more indicates caval reconstruction to avoid postoperative edema of the lower extremity. We did not proceed with vascular reconstruction as clamping of suprahepatic IVC throughout the surgery did not result in hypotension or reduce venous return.

The most important prognostic indicator for IVC leiomyosarcoma patients is surgical resection with negative margins. Other important factors such as tumor grade, size and mitotic rate have been suggested as possible prognostic factors. Type of surgical resection either with or without reconstruction do not determine the significant overall survival, as long as complete resection is performed⁴. If limited resection was performed with reconstruction graft, the risk of tumour recurrence will be higher. The 5-year actuarial survival rate after curative resection is between 28% to 55% for primary leiomyosarcoma of IVC⁵. In three large series with sufficiently large populations and satisfactory follow-up, actuarial survival rates at 5 years after radical resection with curative intent were 53.3% (Hines et al 1999-14 cases), 33% (Hollenbeck 2003-25 cases), and 34.8% (Kieffler et al 2006-22 cases)⁴. The surgery to the IVC is combined with adjuvant radiotherapy and chemotherapy when the tumour is not completely resected, presence of recurrence or metastatic disease, however the efficacy is still debatable by various authors⁴. Unfortunately, most of the survivors actually suffered from local recurrences and distant metastases; as similar thing happened to our patient after 2 years.

CONCLUSION

IVC tumour usually presented at advanced stage thus making the management become more challenging and difficult. Surgery in combination with adjuvant therapy constitutes the only hope of prolonged survival.

REFERENCES

1. Aram Baram, Zirak Anwar Tayeb, Delan Ahmad Bakir. A Rare Retroperitoneal Mass : Leiomyosarcoma of the Inferior Vena Cava. *World J Cardiovasc Surg.* 2014 (4), 51-55.
2. Mete Hidiroglu, Aslihan Kucuker, Ayseguk Kunt. Diagnosis and management of inferior vena cava leiomyosarcoma:review of the literature with a case presentation. *Turk Gogus Kalp Dama.* 2013;21(3):858-863
3. Jean Hardwigsen, Patrick Baqué, Bernard Crespy. Resection of the Inferior Vena Cava for Neoplasms With or Without Prosthetic Replacement: A 14-Patient Series. *Ann Surg.* 2001 (233) , 2, 242–249
4. Edouard Kieffer, Mustapha Alaoui, Jean-Charles Piette. Leiomyosarcoma of the Inferior Vena Cava. *Ann Surg.* 2006 Aug; 244(2): 289–295.
5. Saptarshi Biswasa, Arpit Amina, Suhaib Chaudry, Saju Joseph. Leiomyosarcoma of the Inferior Vena Cava - Radical Resection, Vascular Reconstruction and Challenges: A Case Report and Review of Relevant Literature. *World J Oncol.* 2013;4(2):107-113