

# Pseudomyxoma peritonei: Revisited\*

BY MARY GRACE O. CHENG, MD; LYLAH D. REYES, MD, MSC, FPOGS AND ROMMEL Z. DUEÑAS, MD, FPOGS, FSGOP

Department of Obstetrics and Gynecology, Far Eastern University - Nicanor Reyes Medical Foundation Medical Center

## ABSTRACT

Bleeding after menopause raises suspicion of malignancy; more so, if combined with increased abdominal girth and constitutional symptoms. This is a case of a 74-year-old Gravida 10 Para 8 (8026) who presented with generalized abdominal pain, enlargement, bloatedness and vaginal bleeding. Ultrasound revealed a complex abdominopelvic mass, likely ovarian in origin. Tumor markers CA-125 and CA-199 were elevated. Endometrial curettage with frozen section revealed Leiomyosarcoma.

It was followed by exploratory laparotomy revealing gelatinous material in the peritoneum with seeding of mucoid material into the omentum, ovary and appendix. Frozen section of the right ovary revealed Atypical Mucinous Proliferative Ovarian Tumor (APMOT). Final histopathology result of the endometrial curetting revealed adenomatoid tumor of the uterus. Immunohistochemical staining with desmin and caldesmon revealed negative results implicating the absence of leiomyosarcoma. Final histopathology results were consistent with Disseminated Peritoneal Adenomucinosi (DPAM). Immunohistochemical staining with CK20 was positive and CK7 was negative, consistent with metastases from a primary gastrointestinal tumor. Chemotherapy in the form of FOLFOX regimen was contemplated. However, the patient was lost to follow up.

*Keywords: atypical, adenomucinosi, disseminated, mucinous, ovarian tumor, pseudomyxoma peritonei*

## INTRODUCTION

Borderline ovarian tumors comprise about 15% to 20% of all epithelial ovarian malignancies<sup>1</sup> and the mucinous type accounts for 42.5%. The mucinous type has two common subtypes that comprise about 85% of either the gastrointestinal or enteric subtype.<sup>2</sup> These tumors are best differentiated by immunohistochemical stain like CK7 and CK20 because majority are metastases from gastrointestinal tract rather than primary.<sup>3</sup> The etiology is achieved once histopathologic confirmation has been made after surgical exploration of the abdominal cavity. Intraoperative findings of diffuse gelatinous mucinous implants may affect the peritoneal surface and omentum or with infiltration of other abdominal organs. This description is known as Pseudomyxoma Peritonei (PMP), which is a rare condition of approximately 2 cases per million individuals.<sup>4</sup> Pseudomyxoma Peritonei generally arises from appendiceal neoplasm and rarely from an ovarian origin. This is how our patient presented thus our objectives: to discuss the clinical presentation, use of diagnostic modalities, management approach, postoperative surveillance and prognosis factors in such cases.

## CASE REPORT

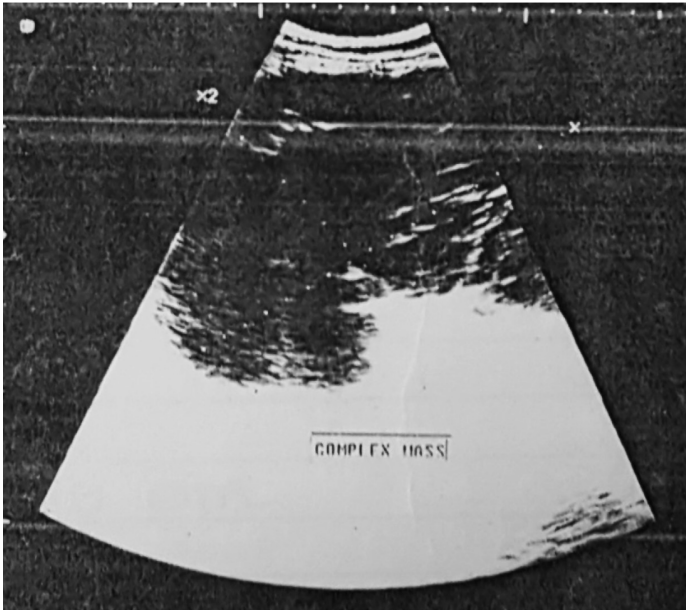
This is a case of a 74-year-old Gravida 10 Para 8 (8026) who presented with 3 months history of generalized abdominal pain, enlargement and bloatedness. This was accompanied by post-menopausal spotting, constitutional symptoms such loss of appetite, early satiety and weight loss.

Two months prior, she consulted in a government hospital in Samar where whole abdominal ultrasound revealed multiple cholelithiases, the largest measuring 0.6 cm, without cholecystitis. The liver, pancreas, spleen, kidneys, urinary bladder and appendix were normal (Figure 1). There was no intraperitoneal fluid collection noted. Transvaginal ultrasound showed a multiseptated mass with minimal solid echogenic components measuring 18.2 x 18 x 16.5 cm in the abdominopelvic area, likely ovarian in origin. The uterus was atrophic. The endometrium was thin at 0.4 cm. Tumor markers CA-125 and CA19-9 were elevated at 87 U/ml and 268 U/ml respectively. She was then referred to our institution for Surgery.

The patient has no co-morbidities such as hypertension, diabetes mellitus, dyslipidemia or thyroid disease. She has no familial history of cancer. She is a 20 pack-year smoker and occasionally drinks alcohol beverage. She is fond of eating meat and fried dishes.

She had her menarche at 15 years-old with regular interval of 28 to 30 days, consumed 2 to 3 moderately soaked pads per day, lasted for 4 to 6 days, with associated

\*First Place, Philippine Obstetrical and Gynecological Society (Foundation), Inc. (POGS) Interesting Case Paper Contest, April 19, 2018, 7th Flr., Olive and Citron Function Rooms, Richmond Hotel, Iloilo City



**Figure 1.** Transabdominal ultrasound showing a huge multiseptated pelvo-abdominal mass with minimal solid echogenic components measuring 18.2 x 18.0 x 16.5 cm.

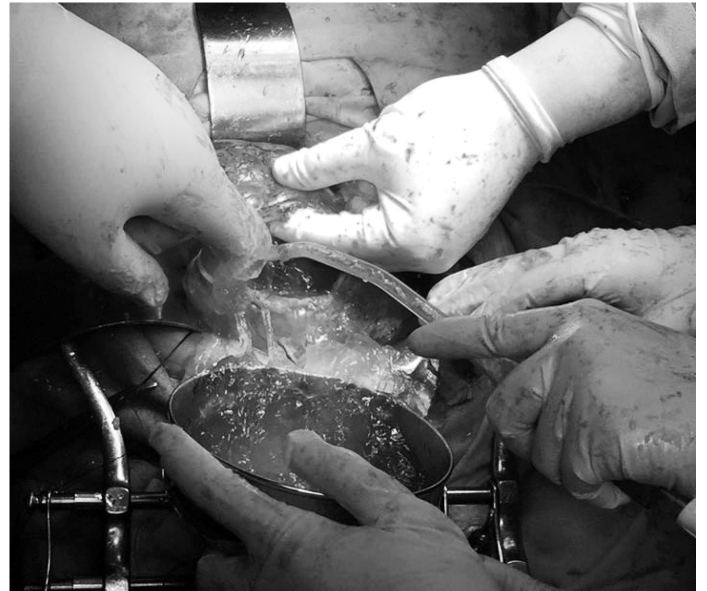dysmenorrhea. She has been menopausal for 24 years. Latest Pap smear was done in 2015, which revealed negative findings for intraepithelial lesion or malignancy. She denied use of oral contraceptive pills. Coitarche was at 16 years-old with 1 lifetime sexual partner. All her pregnancies were carried to term and delivered vaginally except for the last two, which were aborted spontaneously. She delivered her first pregnancy at the age of 20 years-old. She did not breastfeed her children.

Physical examination upon admission showed an ill-looking woman, with slight cachexia in physique and with a BMI of 23. She had stable vital signs and did not appear to be in respiratory distress. Pertinent findings noted were a globularly enlarged abdomen with a circumference of 94 cm, dull on percussion, with a firm, moveable, tender pelvo-abdominal mass measuring approximately 34 x 30 cm mass. Pelvic examination confirmed the above findings. The uterus was not palpated due to the said mass. There was no palpable lymph node enlargement on the inguinal area.

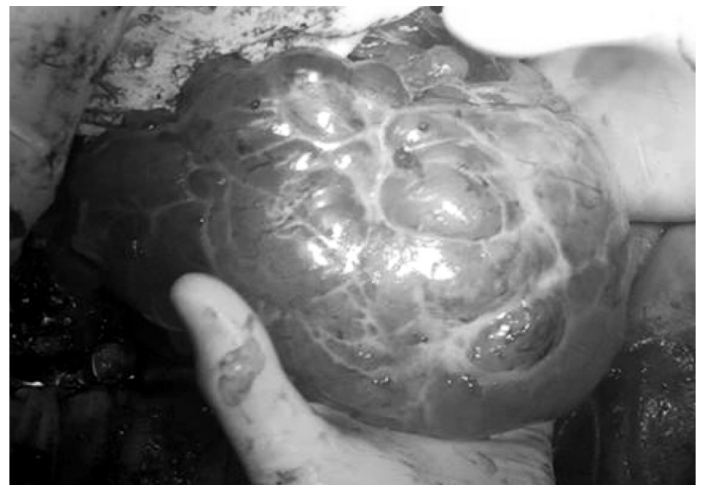The patient was admitted. Computed Tomography (CT) scan was done which revealed large ill-defined multiloculated, multiseptated pelvo-abdominal mass, with cystic and solid components measuring 20 x 11 x 20 cm consistent with ovarian malignancy. Also noted were multiple conglomerated omental masses with presence of mesenteric and retroperitoneal nodules consistent with lymphadenopathy. Marked ascites was also seen. Referral to Gyne-Oncology service was done.

After cardiopulmonary evaluation, she had exploratory laparotomy. Upon opening of the abdomen, there was straw colored gelatinous material amounting to 900 ml noted in the peritoneal cavity (Figure 2). The

liver edge, subdiaphragmatic surface and spleen were smooth. The right ovary was grossly converted to a 15 x 15 x 10 cm multiloculated, predominantly cystic mass with a 1 cm point of rupture at the posterior wall (Figure 3). Frozen section of the right ovary was consistent with atypical proliferative mucinous tumor. The left ovary was converted to a multiloculated, predominantly cystic mass, measuring about 25 x 20 x 15 cm, with a 2 cm point of rupture at the posterior wall, with mucinous fluid draining from within.



**Figure 2.** Intraoperatively, straw colored gelatinous material amounting to 900 ml filled the peritoneal cavity.

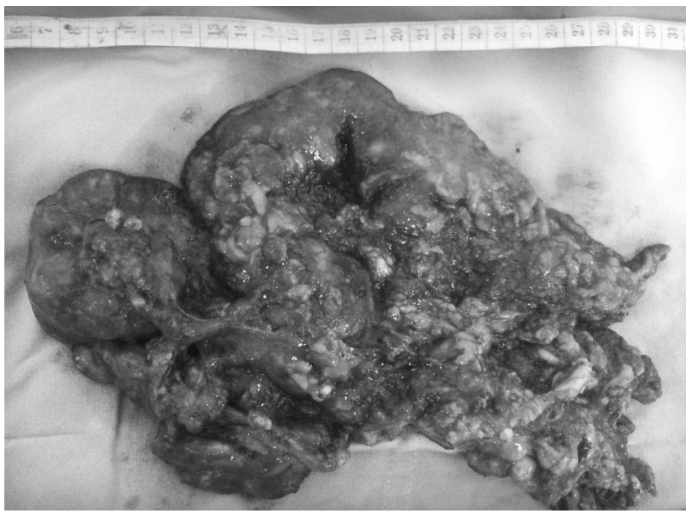

**Figure 3.** Right ovary, grossly converted to a 15 x 15 x 10 cm multiloculated, predominantly cystic mass

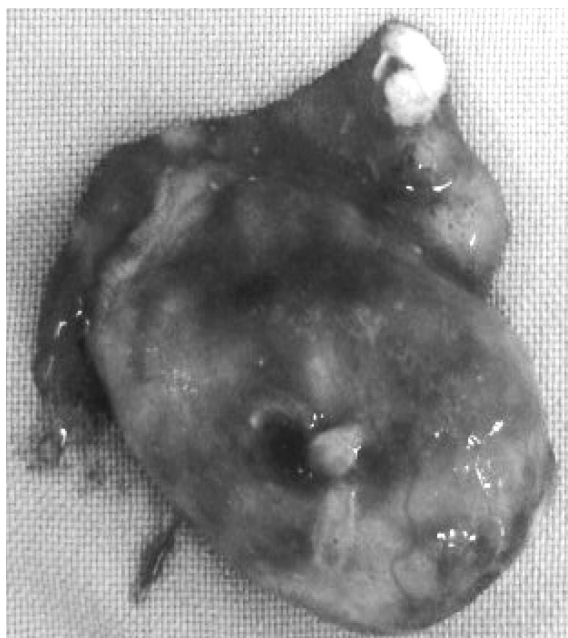The uterus was normal in size and was densely adherent to the sigmoid colon. Caking of the omentum (Figure 4) and multiple excrescences on the bowels were noted. The appendix was bulbous and measured 4 x 3 x 2 cm. Its external surface was gray to brown with prominent

blood vessels (Figure 5). Cut section of the appendix, showed dilated lumen filled with yellow brown mucinous material. Intraoperative referral to gynecologic oncology and surgery was done.

The surgical intervention was exploratory laparotomy, bilateral salpingo-oophorectomy, frozen section of the right ovary (Atypical Proliferative Mucinous Tumor) and endometrium (Leiomyosarcoma), peritoneal fluid cytology, tumor debulking, appendectomy, infracolic omentectomy, adhesiolysis and bowel run under combined spinal and epidural anesthesia. The estimated blood was 1300 ml and the procedure lasted for 4 hours. The patient tolerated the procedure well. The postoperative period was unremarkable. She was discharged after 5 days and was scheduled to follow up after 1 week.

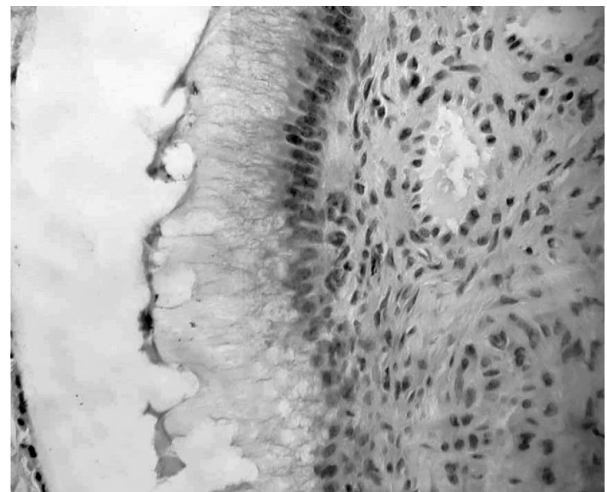


**Figure 4.** Gross caking of the omentum with multiple excrescences

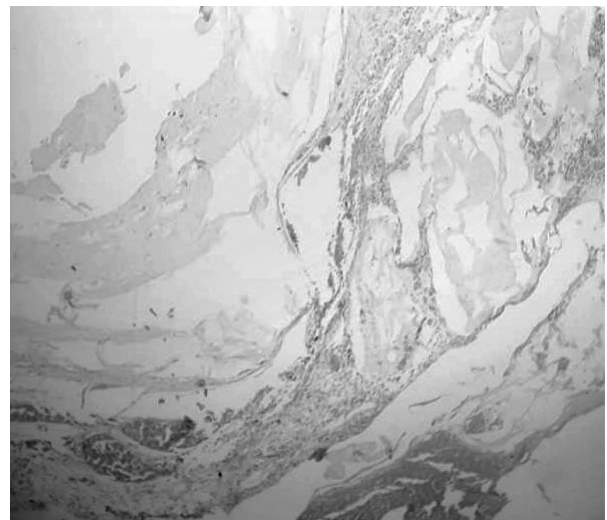


**Figure 5.** Bulbously enlarged appendix measuring 4 x 3 x 2 cm with prominent of blood vessels.

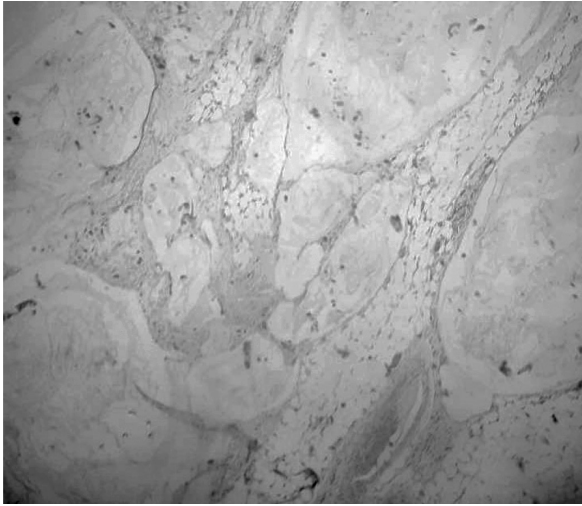
Peritoneal fluid cytology was negative for malignant cells. Final histopathologic reports were as follows: 1. The ovaries were consistent with atypical proliferative mucinous tumor (Figure 6) with involvement of the appendix (Figure 7) and omentum (Figure 8); compatible with disseminated peritoneal adenomucinosis; 2. Endometrial curetting's were consistent with leiomyosarcoma (Figure 9). Immunohistochemical staining of the ovarian tissue was CK7 (Figure 12) negative and CK20 positive (Figure 13) which is consistent with gastrointestinal metastasis. Immunohistochemical staining of the endometrium with caldesmon (Figure 10) and desmin (Figure 11) were both negative consistent with non mesenchymal tumor. The patient was then referred to Medical Oncology service for chemotherapy. However, the patient was lost to follow up.



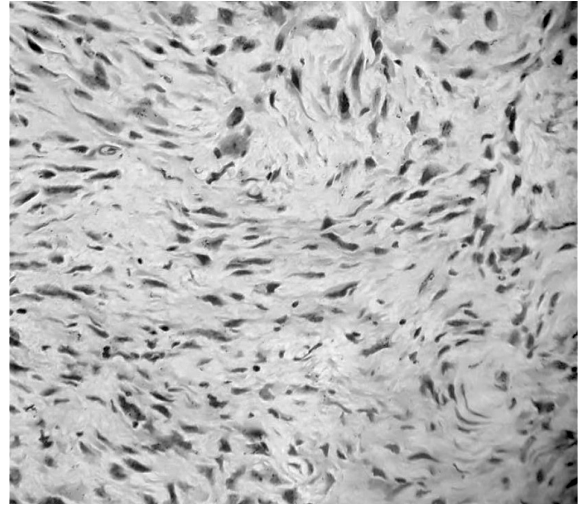
**Figure 6.** Histopath of the right ovary shows partially lined mucin secreting columnar epithelium with several glands within the fibrous stroma. The glands are also lined by mucin secreting epithelium. There are areas where in focal stratification with nuclear atypia of the lining epithelium of some glands are likewise noted involving more than 10% of the sections examined.



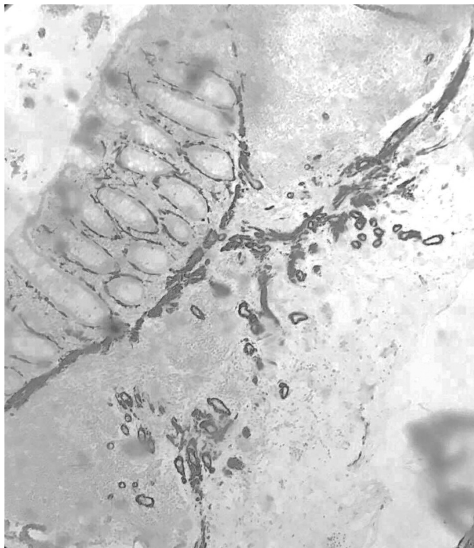
**Image 7.** Histopath of the appendiceal tissue showing glands filled with mucinous material



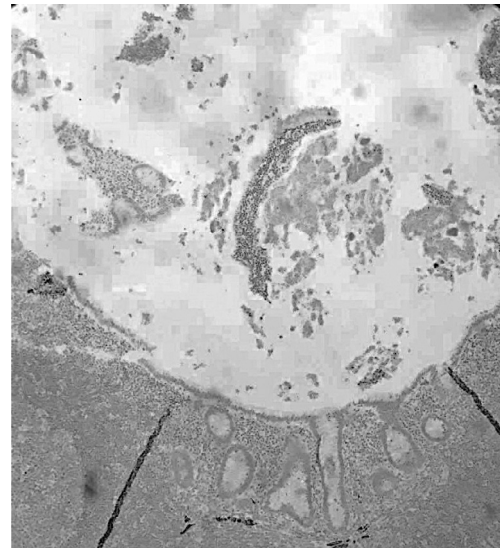
**Figure 8.** Histopath of the fibroadipose tissue from the omentum showing embedded mucinous material and occasional glandular structures.



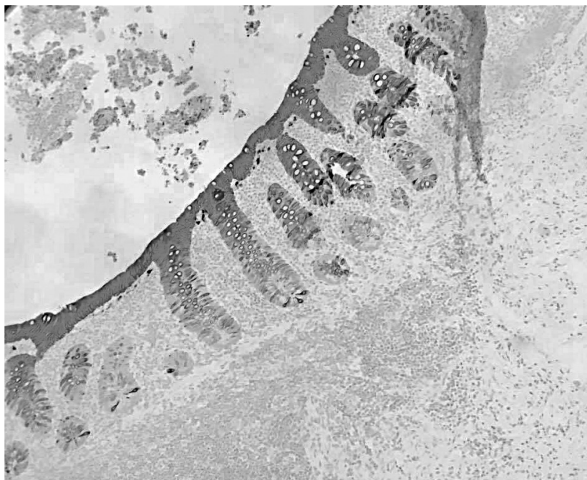**Figure 9.** Final histopath of the endometrial tissue showing absence of nuclear pleomorphism, hyperchromaticity or prominent nucleoli.



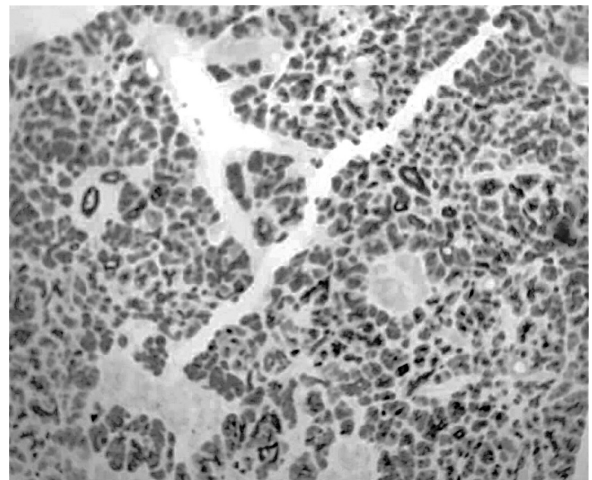
**Figure 10.** Immunostain of the endometrial tissue fragment with Caldesmon - “negative” showing absence of immunoreactivity to smooth muscle components.



**Figure 11.** Immunostain of the endometrial tissue fragment with Desmin - “negative” showing absence of immunoreactivity to smooth muscle components.



**Figure 12.** Immunostain of the right ovary with CK 7 - “negative” showing absence of immunoreactivity to epithelial-derived antigens.



**Figure 13.** Immunostain wof the right ovary with CK 20 - “positive” showing cross reactivity to epithelial-derived antigens.

## DISCUSSION

In a postmenopausal woman presenting with an abdominal enlargement and scanty intermittent vaginal bleeding, malignancy is highly considered. Thus, preoperative evaluation of the clinical features and pathologic findings are equally important in searching for the organ of origin, extent of lesion or nature of the disease if its either benign or malignant.

Clinically, the gynecologist should distinguish if the pathology is gynecologic or gastrointestinal in origin. Among the gynecologic etiologies, the organs that should be investigated include the ovaries and the uterus. The most common symptoms reported by women with ovarian tumors are pelvic or abdominal pain (44%) and increased abdominal girth without palpable abdominal mass (39%). Other symptoms include bloating, bladder and bowel symptoms (15%) and constitutional such as early satiety and weight loss.<sup>6</sup> With regards to uterine pathology, the predominant symptoms are abnormal vaginal bleeding, abdominal pain or discomfort and enlarged pelvic mass.<sup>1</sup> These were all present in our case. With regards to gastrointestinal pathology, the manifestations that can be observed are early satiety, loss of appetite, weight loss, nausea and vomiting, abdominal pain, abdominal mass and constipation. All of these were also observed to occur in this case except for vomiting.

Clinical history and physical examination are important for diagnosis and subsequent management. A thorough abdominal and pelvic examination with bimanual palpation is imperative for further evaluation. As with this case, a huge moveable tender pelvo-abdominal mass measuring 34 x 30 cm, cystic with solid areas with regular borders was palpated on the left lower quadrant. A systematic pelvic examination should include a detailed inspection of the vulva and vagina, particularly looking for atrophy and suspicious lesions. A speculum examination should be performed in order to evaluate the cervix for polyps and cancer.<sup>3</sup> The speculum examination for this patient was unremarkable. At the time of examination, no bleeding was noted. A bimanual examination to evaluate uterine size and mobility, as well as the adnexae with rectal examination completes the assessment of the pelvis.<sup>6</sup> With the clinical presentation and physical examination findings, it is difficult to delineate the origin of the large mass whether the pathology is gynecologic or gastrointestinal in nature. The next step involves the use of appropriate diagnostic modality that is both precise and economical.

Ultrasound is broadly accepted as a highly accurate pre-operative method in discriminating between benign and malignant adnexal masses.<sup>2</sup> Correctly discriminating between benign or malignant adnexal masses is the

essential starting point for optimal management. The role of transvaginal ultrasonography remains the standard for the evaluation of adnexal masses. The sensitivity of transvaginal ultrasound ranges from 86 to 91 percent and the specificity from 68 to 83 percent.<sup>5</sup> On the other hand, the sensitivity of pelvic ultrasound for diagnosis of adnexal mass is 53 to 89% and specificity of 98%.<sup>7</sup> Combination of pelvic and transvaginal ultrasound is a good technique to allow thorough evaluation of masses particularly the huge pelvo-abdominal mass in extent. In addition, color Doppler sonography can be complimentary in increasing the diagnosis.<sup>8</sup> In this case, the sonologist already visualized the huge pelvo-abdominal mass through transvaginal ultrasound and pelvic ultrasound was done to further evaluate the mass. The transvaginal ultrasound result for this case revealed a multiseptated complex mass with minimal solid echogenic components in the abdomino-pelvic area measuring 18.2 x 18 x 16.5 cm, likely ovarian in origin. Though, laterality of the mass was not delineated.

To discriminate the possible gastrointestinal association of the mass particularly the digestive tract accessory organ diseases such as the appendix, gallbladder and spleen, the use of pelvic ultrasound may be helpful. The sensitivity of pelvic ultrasound is 47.8% while the specificity was not calculated due to limitations in capturing patients with true negative results.<sup>5</sup> Pelvic ultrasound has advantages over other diagnostic imaging techniques such as the Computed Tomography (CT scan) in terms of radiation exposure. However, most studies found that the ultrasound has inferior accuracy in identifying origin of the abdominal masses. For superior accuracy in the detection of the organ affected in pelvo-abdominal masses, CT scan is more widely used. For adults, the pooled sensitivity and specificity are both 94%.<sup>10</sup> For this case, CT scan showed a large ill-defined multiloculated, multiseptated abdomino-pelvic mass, with cystic and solid components measuring 20 x 11 x 20 cm; multiple conglomerated omental masses with presence of mesenteric and retroperitoneal nodules consistent with lymphadenopathy and marked ascites.

Magnetic Resonance Imaging (MRI) may also be used in examination of such masses. MRI scan has a sensitivity of 97% and specificity of 95%. However, MRI and CT scan does not provide higher sensitivity and specificity as compared to transvaginal ultrasound to differentiate malignant and benign ovarian tumors.<sup>11</sup> Both CT scan and MRI are very costly as compared to ultrasound. For this case, MRI was not necessary since the transvaginal ultrasound and CT scan were able to establish that the origin of the abdominal mass is ovarian in etiology.

To strengthen the probability of malignancy detected by ultrasound, the tumor markers may be useful in further identifying whether the mass is benign or malignant. Tumor marker CA-125 is done in patients with symptoms

suggesting the presence of a malignant ovarian tumor.<sup>12</sup> If the level is greater than 35 U/mL for postmenopausal women, it further strengthens the diagnosis of ovarian cancer. This has a sensitivity of 69 to 97 percent and a specificity of 81 to 93 percent in diagnosing ovarian cancer. In this case, CA-125 was elevated at 87 u/ml (Normal value: <35 U/ml) and this confers the presence of an ovarian malignancy. The value of other tumor markers, such as CA19-9 and CEA, is to rule out tumors of gastrointestinal origin<sup>13</sup>. The documented specificity of CEA is 30 to 80% for colorectal cancers. It may be undetectable or present only in low concentrations in poorly differentiated tumors. It has a sensitivity of 40% but is non-specific since it can also be elevated in non-colorectal tumors such as gastric, cervical and non-small cell bronchial carcinomas. For CA19-9, it has a specificity of 90% and sensitivity of 81% for pancreatic carcinoma. Its sensitivity for hepatobiliary disease is 70%, around 40 to 50% for gastric, 30% for colorectal and 15% for breast malignancy. Again, in our index patient an elevated CA 19-9 (268 u/ml; Normal value: 0-37 U/ml) was also noted. Hence, other type of carcinomas such as gastrointestinal in nature cannot be totally ruled out for this case.

The availability of both sonographical studies and tumor markers provide a mode to increase the diagnostic accuracy in cases such as this; which is important in order to prepare for the optimal management. The risk of malignancy index (RMI) (Table 1) incorporates the

**Table 1.** Risk of Malignancy Index (RMI), of the index patient. The scores obtained from the ultrasound and menopause status parameters are multiplied by the CA- 125 measurement, 87 U/ml giving a product of 522. The cut off is set at 200 to indicate malignancy.

Ultrasound (Score: 1 point each)	Menopausal Status Score: 1 point for pre-menopause 2 points for menopause	CA-125
1 pt- Multiloculated cyst	2 pts- Menopause	87
1 pt- Presence of solid areas		
Presence of metastasis		
Presence of Ascites		
Presence of bilateral lesion		
<b>Score: 2</b>	2	87
<b>RMI Total Score: 348</b>		

ultrasound finding, CA 125 level and post-menopausal status of the patient. It remains the most widely used prediction model for characterizing ovarian pathology as it has a sensitivity of 85% and a specificity of 97%. The ultrasound parameters showed a multiseptated mass with solid areas, obtaining a score of 2. For the menopause status, a score of 2 was also given. The scores obtained from the ultrasound and menopause status parameters are multiplied by the CA- 125 measurement, which is 87 U/ml giving a product of 348 in our patient. The cut off is set at 200 to indicate malignancy.<sup>14</sup> Due to computed RMI and the presence of ascites and metastases from the CT scan result, she was referred to Gyne-Oncologist due to the increased risk for malignancy findings.

The recommended management for a postmenopausal woman presenting with an enlarged ovarian mass suggestive of malignancy is exploratory laparotomy. Since the patient also presented with post-menopausal bleeding, it is recommended to perform endometrial curettage. Surgical approach will vary once endometrial malignancy is established; wherein extrafascial hysterectomy with bilateral salpingoophorectomy (EHBSO) will be the recommended surgery of choice. On the other hand, ovarian pathology in the absence of endometrial malignancy, total hysterectomy with bilateral salpingoophorectomy (TAHBSO) with complete surgical staging may be done. In some cases, frozen section of the endometrial curettings is used to identify possible endometrial malignancy.<sup>15</sup> The frozen section of the endometrial curettings in our case revealed poorly differentiated spindle cell tumor suggestive of Leiomyosarcoma (Figure 11). Hence for this case, Exploratory Laparotomy, Extrafascial hysterectomy, bilateral salpingo-oophorectomy (EHBSO) was the recommended surgery of choice.

Upon opening of the abdominal cavity of the patient, straw colored gelatinous peritoneal fluid was noted (Figure 2). The liver edge, subdiaphragmatic surface and spleen were smooth. The uterus was smooth and normal in size; however, it was densely adherent to the rectosigmoid colon. Bilateral ovaries were converted into multiloculated cystic masses (Figure 3) and the greater omentum was converted into a bulky thickened mass with multiple excrescences on the bowels were noted (Figure 4). The appendix was bulbously enlarged with prominent blood vessels (Figure 5). The surgery done in this case was incomplete due to difficulty encountered during dissection and the procedure done was bilateral salpingoophorectomy with frozen section of the right ovary, tumor debulking, appendectomy omentectomy, and adhesiolysis.

Microscopic examination of an ovarian mass by intraoperative frozen section is necessary to determine

the histology and grade of the ovarian tumor with a sensitivity of 100%, and a specificity of 95.9%.<sup>18</sup> In our case, the intraoperative frozen section of the right ovary is an atypical proliferative mucinous tumor (APMT) (Figure 6). This finding was consistent with the final histopathology report. On the other hand, rush frozen section of the endometrial curettings was leiomyosarcoma however, the final histopathology report was an adenomatoid tumor of the uterus. Due to these discrepancies, caldesmon and desmin were done which both were negative (Figures 10, 11) implicating the absence of leiomyosarcoma. Final histopath report confirmed involvement of the appendix (Figure 7), and omentum (Figure 8); compatible with disseminated peritoneal adenomucinosis (DPAM).

Ronnett et al. (1995) classified 109 cases of pseudomyxoma peritonei into a low-grade variety, diffuse peritoneal adenomucinosis (DPAM) and a high-grade variety, peritoneal mucinous carcinomatosis (PMCA). In the study, adenomucinosis was defined as a peritoneal neoplasm composed largely of mucin associated with fibrosis, containing scanty strips of simple to focally proliferative mucinous epithelium with minimal cytologic atypia and rare mitotic figures. The primary appendiceal tumor was an adenoma. In contrast, diagnosis of peritoneal mucinous carcinoma is made when the primary tumor was an appendiceal mucinous adenocarcinoma with peritoneal tumors characterized as having more abundant, proliferative epithelium, glands, nests, or individual cells, including signet ring cells, and demonstrated marked cytologic atypia.<sup>24</sup>

*Pseudomyxoma peritonei* (PMP) is an intraoperative clinical finding of mucus or gelatinous fluid in a localized or generalized form, occupying the pelvic or abdominal cavity with involvement of the omentum. Occasionally the gelatinous material forms masses that adhere to the organs of the cavities. The mucus material sometimes infiltrates the stroma of intra-abdominal organs. These were all present in our index patient. These peritoneal implants are the result of incorporation or implantation of mucus and epithelium on the ovarian surface.<sup>19</sup> Most of the PMP that is ovarian in origin maybe associated with mature cystic teratoma and primary ovarian mucinous tumors usually occur as unilateral. Our index patient's histopath result is borderline mucinous tumor. There is also bilateral involvement of the ovaries, wherein the right ovary measured 15 x 5 x 10 cm and the left ovary measured 25 x 20 x 15 cm. Another determining factor to differentiate the primary or metastatic nature of the mucinous neoplasm is the size of the ovarian tumor. Primary mucinous tumors of the ovary are large with a mean diameter of 20 cm. In contrast to metastatic mucinous tumors, which are on average about 10 cm in diameter exceptions are those of pancreatic, small and large bowel in origin that usually

produce large and cystic tumors.<sup>21</sup>

Microscopically, various studies reported that tumors of the ovary and appendix have similar or identical histological features.<sup>20-22</sup> Many of the mucinous tumors found in the ovary are metastases from tumors in other parts of the gastrointestinal tract, particularly the vermiform appendix. This claim was supported by Prayson et al. who concluded that the appendix is the primary site in cases presenting with ovarian tumors associated with disseminated peritoneal adenomucinosis<sup>22</sup> and with Ronett, B.M. who concluded that about 75% of mucinous ovarian tumors are metastatic rather than primary.<sup>4</sup>

For this case, immunohistochemistry is another modality useful in differentiating whether a tumor is a primary carcinoma or metastases. Currently, CK7 and CK20 are considered the standard panel for differentiation of carcinomas that are of ovarian and gastrointestinal in origin. The combined expression of CK7 and CK20 is the most widely used marker. Gastrointestinal carcinomas are CK7 negative and CK20 positive, whereas primary ovarian mucinous carcinomas are CK7 positive and CK20 negative.<sup>22</sup> In this case, the tumor was negative for the CK7 marker and positive for the CK20 marker (Figures 12, 13) consistent with metastases from a primary gastrointestinal tumor.

With the above findings, these strengthen our consideration that the primary lesion was the appendix. But how did these tumor developed and metastasize? Initially, the tumor grew and occluded the lumen of the appendix until mucus accumulated. Then the tumor cells are disseminated through the wall of the appendix into the peritoneal space.<sup>23</sup> The peritoneum was then seeded with mucus-producing cells, which continue to proliferate and produce mucus affecting the bowels. It also has implanted the ovaries, which in turn produced mucinous fluid within, hence the APMOT. It also spread to the uterus, possibly through the fimbrial opening and implanted in the myometrium hence the adenomatoid tumor of the uterus. The progressive accumulation of copious amounts of mucinous fluid gradually filled the peritoneal cavity that caused the abdominal enlargement.

Aggressive debulking and intraperitoneal chemotherapy are the recommended management in an attempt to treat cases of Pseudomyxoma peritonei. The Sugarbaker procedure which consists of surgery debulking resection of all gross disease, cytoreductive surgery combined with chemotherapy or cytoreductive surgery and an intraperitoneal chemotherapy (IPEC) with mitomycin C and 5 Fluorouracil (5-FU) was proven to be of benefit. The IPEC therapy should be initiated during the 1<sup>st</sup> 6 days post operatively. It is directly instilled into the peritoneal cavity for 3 adjuvant cycles.<sup>25</sup> The FOLFOX therapy is another chemotherapeutic agent that is

used widely as a first line adjuvant therapy. This is comprised of Folinic acid (FOL), Fluorouracil (F) and Oxaliplatin (OX). The treatment consists of 6 months of treatment given intravenously every 2 weeks. It is started within 6 to 8 weeks after primary surgery.<sup>26</sup> The FOLFOX was recommended in this case because of the availability of FOLFOX in the country as compared to IPEC. Also, the route of delivery of FOLFOX intravenously is easier compared to direct instillation in the peritoneal cavity with IPEC. Our index patient did not receive any form of adjuvant treatment.

Without treatment, the 5-year survival rate for DPAM group is 84% and 6.7% for the PMCA group. In a follow-up study, Ronnett et al. reported that without aggressive management the DPAM group had a 10-year survival of nearly 70%, whereas patients with PMCA had a 10-year survival of less than 5%.

Mortality due to the disease ranged from 2 to 31% with deaths occurring from 6 months to 12 years after diagnosis; with mean survival at 9 years. Reported complications of the procedure were anastomotic leaks, fistula formation, wound infection, small bowel perforation or obstructions and pancreatitis<sup>10</sup> or this can be due to intra abdominal mucus accumulation accompanied by fibrosis and complicated by small bowel obstruction.<sup>24</sup>

Currently it has been 3 years from the time the patient underwent surgery. On inquiry with a relative, the patient in this case is well with her quality of life restored. No subjective complaint was reported. We have advised and encouraged the relatives to convince the patient to follow-up to optimize delivery of health care in her case.

## CONCLUSION

Overall, it can be said that pre-operative diagnosis essentially depends on clinical judgment. This will be based on thorough history, physical examination, ultrasound findings as well as assessment of tumor markers.

The rarity of DPAM, the risk factors and typicality of the presentation of the symptoms initially pointed to a consideration of an ovarian malignancy. Hence it is recommended that in cases of complex pelvo-abdominal masses, tumors of gastrointestinal origin should always be considered. Transvaginal ultrasound is an excellent tool in discriminating between malignant and benign adnexal masses through IOTA scoring. While CT scan is superior in detection of the organ affected.

Surgery is the recommended procedure in cases wherein a malignancy is considered. The best approach for DPAM is cytoreductive surgery through Exploratory laparotomy with Total abdominal hysterectomy with serial tumor debulking and peritonectomy coupled with IPEC therapy; however in the Philippines setting FOLFOX therapy is more commonly used. Final histopathology result is superior compared to frozen section. When difficulties arise, the use of immunohistochemical stains to exclude malignancy such as leiomyosarcoma and to differentiate between primary and metastatic lesion was proven to be of significance.

The histopathology type and long term prognosis as well as the patient's desire and financial cost should always be considered. Evidences showed long disease free interval with the histopathologic type present in this case. Use of chemotherapy after surgery could have been beneficial in prolonging life however will drastically affect its quality. ■

## REFERENCES

1. Katsube Y, Berg JW, Silverberg SG. Epidemiologic pathology of ovarian tumors: A histopathologic review of primary ovarian neoplasms diagnosed in the Denver Standard Metropolitan Statistical Area, 1 July-31 December 1969 and 1 July-31 December 1979. *Int J Gynecol Pathol.* 1982; 1:3-16.
2. WC, Bernardo R, Jeffrey LK, Timothy RC, Xiao CW, et al. (200 of Ovarian Tumors. *American Cancer Society.* 97:2631-2642.
3. Skirnisdottir I, Garmo H, Wilander E, et al. Borderline ovarian tumors in Sweden 1960-2005: Trends in incidence and age at diagnosis compared to ovarian cancer. *Int J Cancer.* 2008; 123:1897-1901.
4. Ronnett, BM, et al., Pseudomyxoma peritonei in women: a clinicopathologic analysis of 30 cases with emphasis on site of origin, prognosis, and relationship to ovarian mucinous tumors of low malignant potential. *Hum Pathol.* 1995; 26(5):509-524.
5. Heintz AP, Odicino F, Maisonneuve P, et al. Carcinoma of the ovary. FIGO 26th Annual Report on the Results of Treatment in Gynecological Cancer. *Int J Gynaecol Obstet.* 2006; 95(1):S161-S192.
6. Sutton GP. Ovarian tumors of low malignant potential. In: Rubin SC, Sutton GP, editors. *Ovarian Cancer.* 2nd ed. Philadelphia: Lippincott Williams & Wilkins; 2001. p. 399-417.
7. Pourissa M, Refahi S, Moghangard F. The Diagnostic Accuracy of Abdominal Ultrasound in Detection of Ovarian Mass. *Iran J. Radiol.* 2007; (4):2.
8. Sherman ME, Mink PJ, Curtis R, et al. Survival among women with borderline ovarian tumors and ovarian carcinoma: A population-based analysis. *Cancer.* 2004; 100:1045-1052.
9. Timmerman D, Arneye L, Fischerova D, Epstein E, Melis G.B. Simple Ultrasound Rules to Distinguish Between Benign and Malignant Adnexal Mass Before Surgery: Propective Validation by IOTA Grou. *BMJ.* 2010; 341.



10. Perkins GL, Slater ED, Sanders GK, Prichard JG. Serum Tumor Markers. *Am Fam Physician*. 2003; 68(6):1075-1082.
11. Muto M, Sharp H, Goff B, Falk S. Management of an Adnexal Mass. UpToDate. 2016. Retrieved from <http://www.uptodate.com/contents/management-of-an-adnexal-mass#H10103830>.
12. Roman LD, Muderspach LI, Stein SM, et al. Pelvic examination, tumor marker level, and gray-scale and Doppler sonography in the prediction of pelvic cancer. *Obstet Gynecol*. 1997; 89:493.
13. Uzan C, Kane A, Rey A, et al. Outcomes after conservative treatment of advanced-stage serous borderline tumors of the ovary. *Ann Oncol*. 2010; 21:55-60.
14. National Institute for Healthcare and Excellence (NICE) Guideline. 2012. Ovarian Cancer: Recognition and Initial Management (Clinical Guideline No 122). Retrieved from <http://www.nice.org.uk/guidance/cg122/chapter/appendix-d-risk-of-malignancy-index-rmi-i5>.
15. Berbecar VT, Zeca CE, Aldoescu S, Ivancu C, Draghia A, et al. (2016) Large Borderline Ovarian Tumor: A Case Reports. *Surgery Curr Res* 6:258. doi:10.4172/2161-1076.1000258.
16. Schmeler KM, Tao X, Frumovitz M, et al. Prevalence of lymph node metastasis in primary mucinous carcinoma of the ovary. *Obstet Gynecol*. 2010; 116:269-73.
17. Akhavan, Setareh, Azamsadat Mousavi, and Abbas Alibakhshi. "Diagnosis and Management of Borderline Ovarian Tumor Based on the Iranian Guidelines." *Journal of Obstetrics, Gynecology and Cancer Research* 1.1 (2016).
18. Guo, Hui-Shu, Li Yuan, Ning Wang, Wei De, and Li-Jie Liu. "Citation of This Article." *World J Gastroenterol* 9, no. 2 (2003): 233-237.
19. Amortegui, A, Trucco, Sukumvanch, P; Borderline Ovarian Tumors - Atypical Proliferative Ovarian Tumors Glob. libr. women's med.,(ISSN: 1756-2228) 2013; DOI 10.3843/GLOWM.10247.
20. Amortegui, A, Trucco, Sukumvanch, P; Borderline Ovarian Tumors - Atypical Proliferative Ovarian Tumors Glob. libr. women's med.,(ISSN: 1756-2228) 2013; DOI 10.3843/GLOWM.10247.
21. Prayson RA, Hart WR, and Petras RE. Pseudomyxoma peritonei. A clinicopathologic study of 19 cases with emphasis on site of origin and nature of associated ovarian tumors. *Am J Surg Pathol*. 1994; 18(6):591-603.
22. Riopel MA, Ronnett BM, and Kurman RJ, Evaluation of diagnostic criteria and behavior of ovarian intestinal-type mucinous tumors: atypical proliferative (borderline) tumors and intraepithelial, microinvasive, invasive, and metastatic carcinomas. *Am J Surg Pathol*. 1999; 23(6):617-35.
23. Sugarbaker P, Ronnett B, Archer A, Pseudomyxoma Peritonei Syndrome. *Adv Surg*. 1996; 30:233-80.
24. Wirtzfield D, Rodriguez-Bigas M, Weber T, Petrelli N. Disseminated Peritoneal Adenomucinosis: A Critical Review. *Annals of Surgical Oncology*. 1999; 6:797.
25. Karmarkar P, Joshi A, Wilkinson A, Mahore S, Bothale K. Villous Adenoma of the Appendix with Dysplasia. *Saudi Journal of Gastroenterology : Official Journal of the Saudi Gastroenterology Association*. 2008; 14(1):38-39. doi:10.4103/1319-3767.37807.
26. Bryant J, Clegg A, Sidhu M, Brodin H. Clinical Effectiveness and Cost of Sugarbaker Procedure for the Treatment of Pseudomyxoma Peritonei. *Health Technology Assessment*. 2004; 8(7):5-12.
27. Chen C, Huang C, Kang W, Hsieh J. Experience with Adjuvant Chemotherapy for Pseudomyxoma Peritonei Secondary to Mucinous Adenocarcinoma of the Appendix with Oxaliplatin/ Fluorouracil/ Leucovorin (FOLFOX4). *World Journal of Surgical Oncology*. 2008; 6:118.