

Case Report

Recurrent tongue mass secondary to renal cell carcinoma: A case report

Nurul Syeha Abdull Rasid^a, Farah Wahida Abdul Manab^b, Nor Shahida Abdul Mutalib^b, Irfan Mohamad^{a*}, Hamidah Mamat^b

^a Department of Otorhinolaryngology-Head & Neck Surgery, School of Medical Sciences, Universiti Sains Malaysia Health Campus, 16150 Kota Bharu, Kelantan, Malaysia.

^b Department of Otorhinolaryngology-Head & Neck Surgery, Hospital Sultan Abdul Halim, 08000 Sungai Petani, Kedah, Malaysia.

* Corresponding author: irfankb@usm.my

Submitted: 23/10/2018. Accepted: 25/11/2018. Published online: 25/11/2018.

Abstract Renal cancer is a rare occurrence in all adult malignancies, and renal cell carcinoma (RCC) is the most common type. Due to its aggressive behaviour and high tendency for metastasis, manifestation of RCC varies, often with non-urologic features or symptoms from metastatic sites. Metastatic RCC to the head and neck region is rare particularly to the tongue are extremely rare. We report an elderly lady who presented with recurrent tongue mass metastasis from RCC, a rare cancer with even rarer metastatic site.

Keywords: Neoplasm metastasis; nephrectomy; recurrence; renal cell carcinoma; tongue.

Introduction

Renal cell carcinoma (RCC) is a cancer with aggressive behaviour. It has been associated with rare metastatic sites and atypical presenting symptoms from disseminated disease and distant metastatic sites. RCC is the third most common infraclavicular cancer to metastasize to the head and neck region (Torres-Carranza *et al.*, 2006), outnumbering breast and lung carcinomas. In head and neck metastasis, nose and paranasal sinuses are most commonly affected, followed by the oral cavity (Yoshitomi *et al.*, 2011).

Case report

A 74-year-old female was diagnosed with right renal cell carcinoma who previously had underwent a right radical nephrectomy. After one year, she presented with a painless tip of the tongue

mass. She had no urogenital tract or any abdominal symptoms. Oral examination showed a 1.5 cm x 1 cm irregular and pedunculated mass on the tip of her tongue (Fig. 1). Her tongue mobility was normal and there was no palpable cervical lymphadenopathy. The mass was completely excised and sent for histopathological examination. The result revealed as metastatic RCC.

Two months later, she presented again with bleeding from the oral cavity and difficulty in swallowing. The tongue mass reappeared at the same site but doubled in size. It protruded beyond the oral cavity (Fig. 2). Wide resection with 0.5-1 cm margin was performed (Fig. 3). The histopathological examination showed recurrent metastatic RCC. After 2 months post resection, the operated site was well healed (Fig. 4). The patient had no recurrence; however, she had refused any adjuvant oncological treatment.

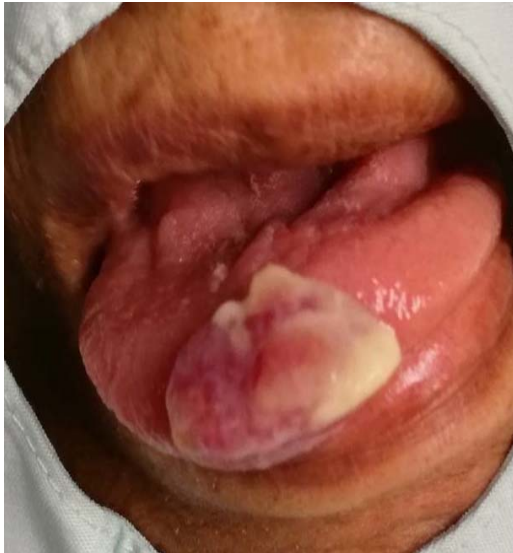

Fig. 1 Tip of tongue mass at the initial presentation which appeared one year after nephrectomy.

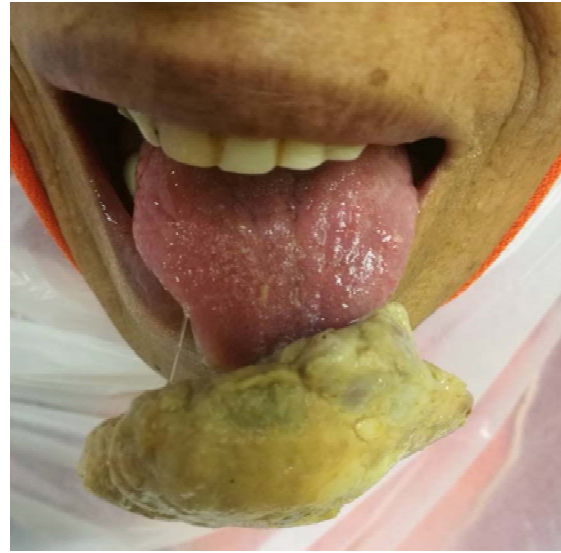


Fig. 2 Recurrence of tongue mass protruded from oral cavity after 2 months following the first surgery.

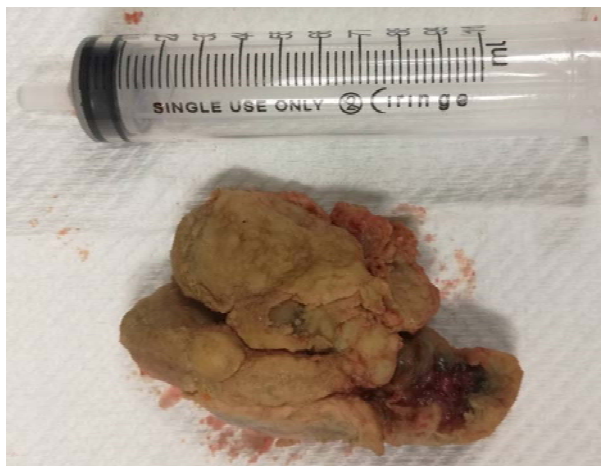

Fig. 3 Metastatic tumour mass which was excised with 1 cm margin.

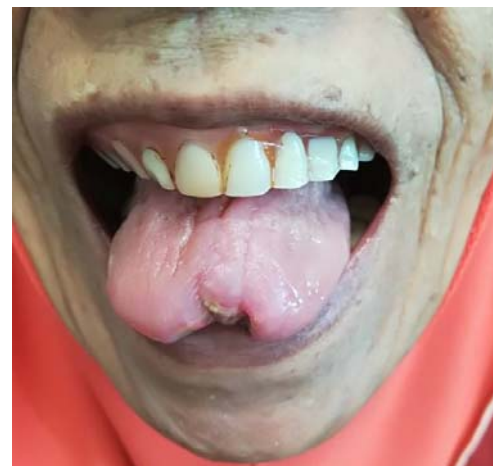

Fig. 4 The healed operated site as seen after 2 months post-surgery.

Discussion

The patterns of metastasis from RCCs are still not well established and well understood (Sountoulides *et al.*, 2011). The potential routes of metastases to the tongue include the systemic circulation, the venous circulation, and the lymphatic circulation. Batson proposed that the valveless vertebral venous plexus serves as a channel for bypassing filtration through the lungs and the increase in intrathoracic pressure directs blood flow towards the head and neck region from the caval and azygos venous systems (Gill *et al.*, 2015).

Wang and Chen had suggested a theory for metastasis to the oral cavity as a combination of hematogenous distribution and retrograde cervical lymphatic spreading through the thoracic duct (Torres-Carranza *et al.*, 2006; Gill *et al.*, 2015).

Tongue metastasis from RCC is associated with poor prognosis and has a median survival of 6 to 8 months (Torres-Carranza *et al.*, 2006; Gill *et al.*, 2015). Five-year survival rates of metastatic RCC is less than 10% (Azam *et al.*, 2008). The treatment of tongue metastasis is palliative and targets pain relief, preventing bleeding and infection as well as airway problems.

Surgical excision is recommended as an option for palliative treatment with preservations of tongue structure and function (Sountoulides *et al.*, 2011).

It is often challenging to differentiate the tongue mass is either primary or secondary lesions, because of the similarity in the gross appearance. A case of metastatic RCC to the tongue was easily misdiagnosed as primary tongue squamous cell carcinoma (Azam *et al.*, 2008). However, generally, primary tongue lesion tends to be fungating, ulcerative rather than pedunculated type in secondary or benign lesion cases. Amongst cases of tongue metastasis from RCC, the mass can be soft and smooth (Yoshitomi *et al.*, 2011), polypoidal or nodular lesion (Balliram *et al.*, 2012) and pedunculated mass (Azam *et al.*, 2008) mimicking primary tongue carcinoma. Yoshitomi *et al.* (2011) who had analysed 29 previously published cases of metastatic RCC to the tongue, reported that the commonly involved area is the base of the tongue followed by dorsum of the tongue, and there were only three cases which involved the tip of tongue. In the present case, the tongue mass was pedunculated and appeared at the tip with a recurrence at the same previous location.

In managing a tongue mass, a thorough evaluation to distinguish between primary and secondary tongue cancer is important although metastases are rare. Therefore, excision biopsy should be performed for early definitive intervention. However, in the present case, as the mass was pedunculated type, complete excision was done for diagnostic as well as therapeutic purposes.

Management of tongue metastasis involved surgical excision and would be followed by adjuvant radiotherapy to attain the local control of the disease even though RCC is known as a radioresistant tumour. Chemotherapeutic agents together with biological agents such as interferon- α can provide a palliative benefit in some patients with RCC. Some researchers reported a complete response in a base of tongue metastasis after interferon- α therapy (Azam *et al.*, 2008). Administration of interferon- α and interleukin-II post resection of the lingual mass had shown a disease-free period of 2 years, even though most

patients succumbed within 1 year after diagnosed of the metastases (Will *et al.*, 2008). Thus, therapeutic decisions should maximize comfort and minimize morbidity considering the poor long-term prognosis at this stage of the disease. In the present case only surgical excision was performed without the adjuvant radiotherapy.

To the best of our knowledge, the present case was the first that reported a recurrent tongue metastasis from RCC which occur at the same location. In five cases of tongue metastasis as first presentation of RCC, surgical intervention was done in four cases as part of diagnostic and therapeutic purposes and recurrence were not documented (Cochrane *et al.*, 2006; Azam *et al.*, 2008). In the present case the recurrence might be due to the incomplete first treatment, as local excision was performed instead of wide resection, and the patient was not on adjuvant radiotherapy. However, after the second surgery, there was no recurrence observed after two months.

The prognosis of RCC with metastasis is poor. A two-year survival rate for RCC metastases of the oral cavity is about 78% and a five-year survival rate of 50% was documented in patients who had metastases after undergoing nephrectomy (Aguirre *et al.*, 1996). The treatment depends on the size and location of the tongue metastatic mass and the patient's condition. Surgical excision in form of wide resection of the tongue mass whenever feasible is suggested as the primary treatment while chemotherapy would help for a short-term decrease in the severity of symptoms, with maximum 2-year survival rates of 24%. Radiotherapy will only provide tumour stasis. More recently, clinical trials using immunotherapeutic approaches have shown promising results. However, further research is needed to develop effective therapeutic agents for the treatment of RCC and its metastases.

Conclusion

Owing to its rarity, the diagnosis of metastatic lesions in oral region had proved to be quite a challenge to both the clinicians and the pathologists to distinguish them from the primary tumours. History plays

major role to understand and to differentiate whether it could be a primary or highly suspicious of metastatic lesion. In the present case, it was best to be treated with wide local resection with good margin. However, as the patient default the subsequent follow-up, the evaluation on the effectiveness of the adjunct radiotherapy in the present case could not be carried out.

References

- Aguirre A, Rinaggio J, Diaz-Ordaz E (1996). Lingual metastasis of renal cell carcinoma. *J Oral Maxillofac Surg*, **54**(3): 344-347.
- Azam F, Abubakerr M, Gollins S (2008). Tongue metastasis as an initial presentation of renal cell carcinoma: A case report and literature review. *J Med Case Reports*, **2**:249.
- Balliram S, Goetz L, Ramsoobhag K, Narinesingh D, Medford S, Naraynsingh V (2012). Renal cell carcinoma presenting as a tongue lesion. *J Oral Maxillofac Surg*, **70**(7): 1605-1608.
- Cochrane TJ, Cheng L, Crean S (2006). Renal cell carcinoma: A rare metastasis to the tongue--a case report. *Dent Update*, **33**(3): 186-187.
- Gill KS, Frattali MA (2015). Colorectal adenocarcinoma metastasis to the tongue. *Case Rep Otolaryngol*, **2015**:242135.
- Sountoulides P, Metaxa L, Cindolo L (2011). Atypical presentations and rare metastatic sites of renal cell carcinoma: A review of case reports. *J Med Case Reports*, **5**:429.
- Torres-Carranza E, Garcia-Perla A, Infante-Cossio P, Belmonte-Caro R, Loizaga-Iriondo JM, Gutierrez-Perez JL (2006). Airway obstruction due to metastatic renal cell carcinoma to the tongue. *Oral Surg Oral Med Oral Pathol Oral Radiol Endod*, **101**(3): e76-e78.
- Will TA, Agarwal N, Petruzzelli GJ (2008). Oral cavity metastasis of renal cell carcinoma: A case report. *J Med Case Reports*, **2**:313.
- Yoshitomi I, Kawasaki G, Mizuno A, Nishikido M, Hayashi T, Fujita S *et al.* (2011). Lingual metastasis as an initial presentation of renal cell carcinoma. *Med Oncol*, **28**(4): 1389-1394.