

CASE REPORT**PURULENT PERICARDITIS SECONDARY TO METHICILLIN-RESISTANT *STAPHYLOCOCCUS AUREUS* IN A PREVIOUSLY HEALTHY INFANT: A CASE REPORT**

Aaron G. Tulay, MD¹
Elizabeth E. Gallardo, MD^{1,2}

¹ Department of Pediatrics, Saint Louis University-Hospital of the Sacred Heart

² Department of Pediatrics, Section of Pediatric Infectious Diseases, Saint Louis University-Hospital of the Sacred Heart

Correspondence:
Dr. Aaron G. Tulay
Email: aaront296@gmail.com

The authors declare that the data presented are original material and has not been previously published, accepted or considered for publication elsewhere; that the manuscript has been approved by all authors, and all authors have met the requirements for authorship.

ABSTRACT

Purulent pericarditis with cardiac tamponade caused by community-acquired methicillin-resistant *Staphylococcus aureus* is rare and fatal. There are limited data in children in the current antibiotic era, and available reports usually involve patients with immune dysfunction and prior thoracic instrumentation or has a thoracic focus of infection. Rapid recognition and treatment are paramount in the survival of patients. We report a case of purulent pericarditis with cardiac tamponade secondary to community-acquired MRSA in a previously healthy 10-month-old male infant who presented with fever, pallor, shock, and cardio-respiratory distress. CBC showed leukocytosis with neutrophilia, markedly elevated inflammatory markers, and cardiomegaly on chest radiography. The ECG showed diffuse concave ST-segment elevation, low QRS voltages on precordial leads, and electrical alternans consistent with pericarditis with probable significant pericardial effusion confirmed by 2D echocardiography with note of cardiac tamponade. He was managed effectively with pericardiostomy in combination with a 4-week course of vancomycin. Blood and pericardial fluid culture grew MRSA. This case underscores the organism's lethality and its potential to infect immunocompetent children without predisposing factors. The value of early recognition, prompt initiation of treatment and management is of utmost importance.

KEYWORDS: *Purulent pericarditis, Pericardiostomy, CA-methicillin resistant Staphylococcus aureus, Case report*

INTRODUCTION

Purulent pericarditis is defined as an infection of the pericardium characterized by frank pus in the pericardial space.¹ It is a fatal infection requiring immediate detection and treatment. In the advent of antibiotics, this has become rare with limited epidemiologic data and accounts for only <1% of all reported cases of infectious pericarditis. This classically affects children with a compromised immune system or those with a history of thoracic instrumentation, surgery, and trauma rather than in healthy children. While a number of pediatric literature reports of purulent pericarditis, there is limited data on community-acquired methicillin-resistant *Staphylococcus aureus* (MRSA) as the etiology in children.¹⁻⁸ There have been studies demonstrating an increase in the incidence of various community-acquired MRSA infections affecting the pediatric population such as soft tissue infections, sepsis, and pneumonia. We report a case of a previously well immunocompetent 10-month-old male infant with purulent pericarditis secondary to a community-acquired methicillin-resistant *Staphylococcus aureus* with characteristics of cardiac tamponade. Specifically, this paper aims to examine its clinical manifestations, emphasize the importance of early recognition, and the benefit of a team approach in its successful management.

CASE REPORT

A previously healthy 10-month-old male infant was admitted in our tertiary hospital presenting with five days history of intermittent febrile episodes with a maximum temperature of 38.9°C with no other associated manifestations such as poor intake, irritability, cough, colds, difficulty of breathing, vomiting, diarrhea, nor skin lesions. Outpatient consultation was done, and he was prescribed with amoxicillin syrup at 30 mg/kg/day for an undisclosed diagnosis. A day before his admission, he manifested with pallor, tachypnea, and poor oral intake.

The patient was born term via normal spontaneous vaginal delivery with good APGAR score and was discharged after 24 hours from birth. Newborn screening result was normal, and he was

exclusively breastfed until 6 months of age with introduction of complementary feeding at 7 months of age. He has no previous hospitalizations nor history of recurrent infections. Prior consultations with a medical practitioner were for well-baby check-ups. Patient had his primary series of vaccination at a health center with the last vaccine dose administered 5 months prior to this admission. Interruptions of vaccinations were due to the lockdowns imposed for the control of COVID-19 pandemic. The patient is developmentally at par with age. His household contacts were apparently healthy with no noteworthy recurrent skin lesions. Family history is likewise unremarkable.

On arrival at the ER, the patient was diaphoretic, pale, and in cardiopulmonary distress. He was febrile at 39°C, tachycardic at 193 beats per minute, tachypneic with a respiratory rate of 80 breaths per minute, systolic blood pressure was 80 mmHg, and his oxygen saturation at room air was 95%. Patient is adequately nourished with weight of 8 kg, length of 70 cm (z-score 0), and the mid-upper arm circumference (MUAC) was 13 cm. Head was normocephalic with no scalp lesions, no conjunctival, nasal, and aural discharges, no oral mucosal ulcerations or inflammation, no cervical lymphadenopathy, with no jugular vein distention. Chest findings included subcostal and intercostal retractions with fine bibasal rales. Heart sounds were muffled, with no murmurs and no friction rub. He had no abdominal distention, no hepatosplenomegaly, with normoactive bowel sounds. On further physical examination, extremities were cold and clammy with weak peripheral pulses and a capillary refill time of 3 seconds. Considerations at this point were myopericarditis, community-acquired pneumonia, and septic shock. Initial laboratory workup showed significant leukocytosis (WBC: 25,000/mm³) with neutrophilic predominance, markedly elevated C-reactive protein (CRP) -249.69 mg/L and procalcitonin -10.87 ng/ml with normal cardiac enzymes. Chest x-ray (Fig.1A) revealed cardiomegaly (CT ratio: 0.63) and minimal streaky densities on the right lower lobe signed out as right lower lobe pneumonia, which was

incongruent with the patient’s degree of distress. Electrocardiography (Fig. 2) demonstrated sinus tachycardia, diffuse concave ST-segment elevation, low QRS voltages on precordial leads, and electrical alternans consistent with pericarditis with a probable significant pericardial effusion; cardiac tamponade was also considered at this point. The patient was started on ceftriaxone (61 mg/kg/day q12 hours) and penicillin (150,000 units/kg/day q6 hours); fluid resuscitation at 20 cc/kg was performed, and dopamine drip at 5 mcg/kg/min was initiated. A stat 2D-echocardiography by an on-call pediatric cardiologist showed a low ejection fraction (38%) and confirmed the presence of a moderate circumferential pericardial effusion with right atrial and ventricular collapse (Fig.3) consistent with tamponade physiology. Emergency pericardiostomy (Fig.4) with pericardial drain placement was done for both therapeutic and diagnostic reasons. Intraoperatively, the pericardial sac was noted to be tensed and upon opening, about 70 cc of purulent fluid was initially drained from the pericardial space (Fig.4). The cardiac surface was noted to be pale with fibrin deposits, pericardial tissue samples were taken for histopathologic studies. Resolution of diaphoresis, return of full pulses, normal heart sounds and improvement of tachycardia and tachypnea were observed during the immediate post-operative period. Because of the purulent nature of the effusion, penicillin was discontinued, and clindamycin (37.5 mg/kg/day q8 hours) was added to the antibiotic regimen.

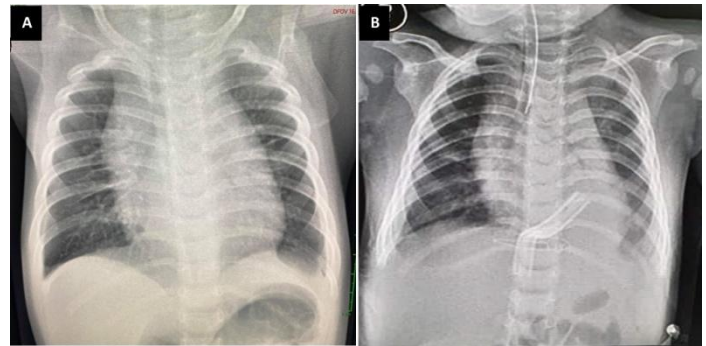


Figure 1: **A.** Initial Chest X-ray showing cardiomegaly with a computed cardiothoracic ratio of 0.63, and minimal streaky densities in the right lower lobe signed out as pneumonia. **B.** Repeat Chest X-ray on APL view on the 3rd post-operative day showed decreased CT ratio (0.56), also visualized was the JP-tube within the pericardial space.

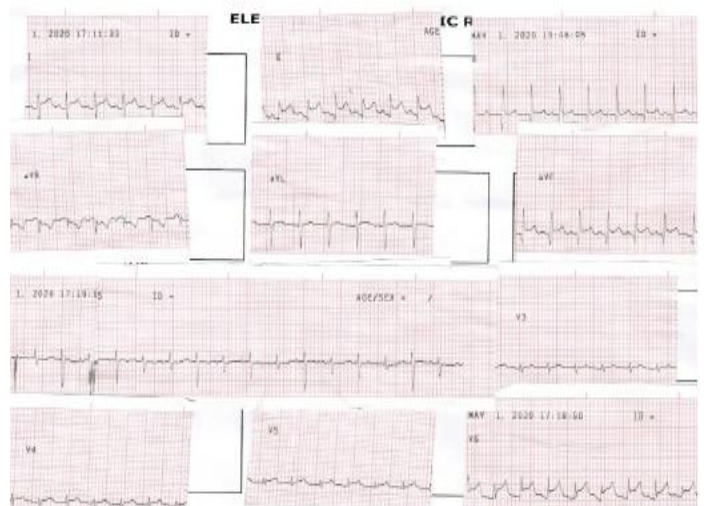

Figure 2: Electrocardiographic changes consistent with pericarditis and pleural effusion in the patient; sinus tachycardia, diffuse concave ST elevation in the lateral and inferior leads; PR depression; alternate beat amplitude of the QRS complex (Electrical Alternans) indicative of pericardial effusion; Low QRS voltage in the precordial leads.

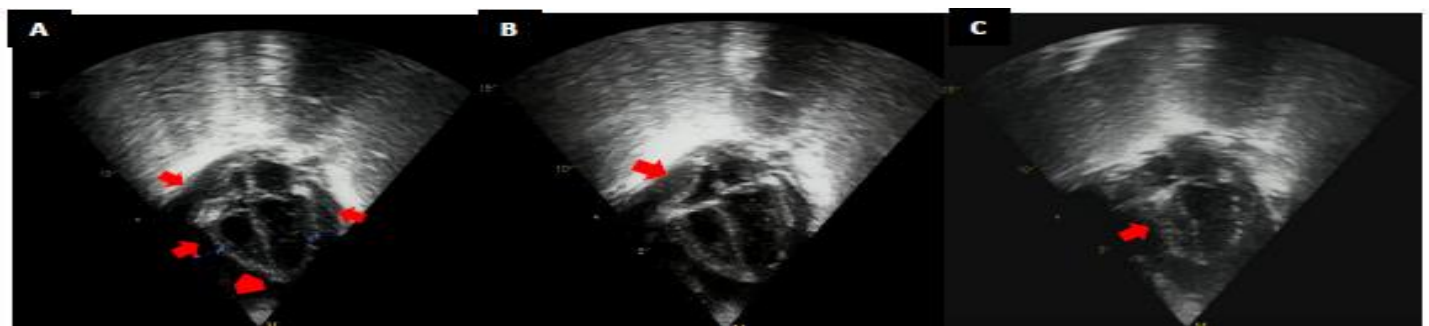

Figure 3: Four chamber view of the patient’s echocardiography and tamponade physiology. **A.** Moderate circumferential pericardial effusion (Red arrows). Left ventricle side: 1.52 cm, Right ventricle side: 1.1 cm, Right atrial side: 1 cm. The red arrow in **B** is pointed to a collapse right atrium, while the arrow in **C** is focused on a collapse right ventricle.

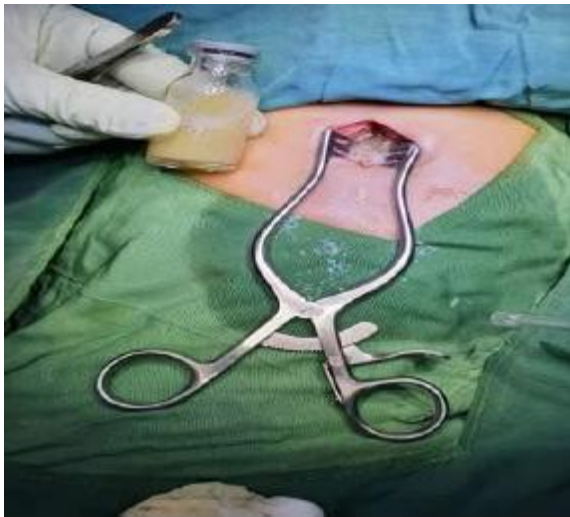

Figure 4: Drainage of a grossly purulent pericardial fluid after pericardiostomy, a JP-tube was placed in the pericardial space for continuous drainage.

Gram stain of the pericardial fluid showed moderate number of gram-positive cocci singly and in clusters and the presence of many wbc/mm³ comprising mostly (82%) of neutrophils, while the pericardial tissue sample demonstrated marked acute and chronic inflammation. Cultures from the pericardial fluid and blood specimens grew methicillin-resistant *Staphylococcus aureus* (MRSA) sensitive to clindamycin, vancomycin, and linezolid. A total of 217 cc of purulent fluid continued to be evacuated from the pericardial drain in the ensuing hospital days. On the 3rd day of admission, cardiac and respiratory rates were down to acceptable limits. A repeat chest x-ray showed a reduction in CT ratio (Fig. 1B), and the electrocardiographic reading was normal; however, the patient remained to have intermittent febrile episodes with temperature of 38-38.6°C. The patient was then referred to the infectious disease service that advised antibiotics be shifted to vancomycin (60 mg/kg/day q6 hours) monotherapy.⁹

The patient was extubated on the 1st postoperative day, weaned from inotrope on 2nd postoperative day, with removal of the pericardial drain on the 12th postoperative day. Repeat laboratory test results on the 12th day of confinement showed a significant reduction in the inflammatory markers – CRP -36.43 mg/L and procalcitonin -0.32 ng/ml, a significantly improved

complete blood count, and negative blood cultures. Serial echocardiography demonstrated resolving pericardial effusion, a normal ejection fraction with no chamber compromise (Fig. 5). His course was complicated by healthcare-associated pneumonia (HCAP) with onset on the 24th hospital day manifesting as febrile episodes with recorded maximum temperature of 38.8°C, tachypnea with respiratory rate of 60/min, CRP was elevated at 102.46 mg/L and repeat chest X-ray revealed new bilateral lower lobe infiltrates. HCAP was treated with seven days of cefepime (150 mg/kg/day q8 hours). The patient was discharged after completing four weeks of vancomycin, adhering to the Philippine National Antibiotic Guidelines on treatment of MRSA purulent pericarditis.⁹ The parents were advised to adhere to the child's follow-up schedule, update his vaccination and seek immediate medical attention if the patient develops signs and symptoms of constrictive pericarditis. Likewise, observance of proper environmental and personal hygiene and limit exposure to non-family members were instructed. Series of echocardiography done after discharge showed no evidence of constrictive pericarditis. Further follow-up consultations until one year following discharge were devoted for vaccination and well-baby follow-up visits.

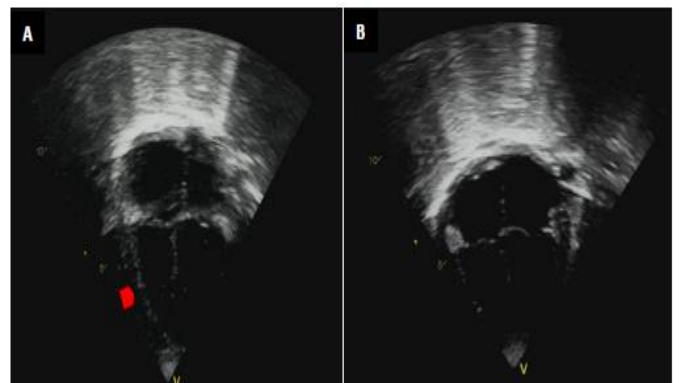


Figure 5: **A.** Patient's echocardiography on the 3rd day after pericardiostomy showing small pericardial effusion (arrow) with no chamber collapse, EF is 68%. **B.** Repeat 2D-echo 25 days post-pericardiostomy demonstrating resolution of pericardial effusion with no evidence of constriction.

DISCUSSION

A diagnosis of pericarditis should be suspected in patients with fever, tachycardia, and tachypnea with evidence of cardiomegaly.²⁻³ As in our case, not all tachypnea is secondary to a lung pathology; pericardial disease states should be considered, especially in patients with moderate to severe cardiorespiratory distress with patient's clinical status not proportional to the patient's lung physical examination findings. In infants, purulent pericarditis commonly manifests with signs of sepsis or shock.¹¹ This condition is often fatal, but if complicated by cardiac tamponade, it becomes a medical emergency, and patient's survival pivots on speedy recognition and initiation of appropriate intervention while anticipating diagnostic test results.^{2,6-7} The cardiac tamponade likely occurred in our patient because of an abrupt accumulation of pericardial fluid secondary to the inflamed pericardium. This increases the intrapericardial pressure past the limit of potential pericardial distention causing constraints in ventricular and atrial filling and decreased cardiac output. Pericarditis and cardiac tamponade present atypically among infants, the classic Beck's triad (muffled heart sound, narrow pulse pressure, and distended neck veins) is present only in 35-40% of cases.²⁻³ The pericardial friction rub, although a pathognomonic physical examination finding for pericarditis, is often absent in the presence of a significant pericardial effusion.^{2,10} The absence of pulsus paradoxus in our patient can be explained by a right-sided tamponade as evidenced by a collapse right atrium and right ventricle, pulmonary hypertension with documented pulmonary artery pressure of 67 mmHg and a left ventricular dysfunction in which the measured ejection fraction was only 38%.¹⁰

Patients with pericarditis or pericardial effusion may present with normal appearing cardiac shadow while some will have cardiomegaly on chest radiography, and with increasing effusion, the cardiac silhouette may adopt a flask shape, with normal pulmonary vascular markings.^{2-6,10} As seen in our patient, electrocardiography usually shows ST

segment elevation in the lateral or inferior leads, and PR interval depression.²⁻³ The occurrence of low QRS voltages and electrical alternans are observed in the presence of significant effusion.¹ Echocardiography remains to be the most sensitive technique for identifying and locating pericardial effusions while detecting evidence for tamponade, and relatedly, a 2D-echo guided pericardiocentesis is the preferred diagnostic and therapeutic option.^{2,10} However, the surgical intervention performed by the team of thoraco-vascular surgery in our patient in draining the effusion is pericardiostomy instead of a pericardiocentesis due to the sizeable circumferential nature of the pericardial effusion with certainty that posteriorly located effusion cannot be approached by the latter. When challenged by a bacterial purulent pericarditis, empiric broad spectrum parenteral antibiotics should be administered immediately and the selection of antibiotics should cover for the potential causative agents including *S. aureus*, *S. pneumoniae* and other streptococci species, *H. influenzae*, *N. meningitidis*, and enteric bacilli.^{2-3,9} Evidence recommends the use of at least two antibiotics especially when the etiologic organism cannot be identified promptly, however, antibiotics are then directed to the causative organism once culture result is available.^{3,9,11} These recommendations were followed in the antibiotic treatment regimen of our patient.

MRSA is frequently linked to hard-to-treat infections. MRSA infections causes significant morbidity, mortality, longer hospital confinement, social and economic burden.¹² Over the past decades, MRSA became an important healthcare-associated pathogen, complicating the care of surgical, chronically ill, and intensive care unit patients. Treatment is challenging, due to its resistance to multiple antibiotics. In the late 1990s, MRSA emerged as a community pathogen, hence the term CA-MRSA.¹¹⁻¹⁴ It has been found to cause a variety of diseases, ranging from asymptomatic colonization to invasive infections. However, the host and bacterial factors driving these dynamics are poorly understood.¹³ CA-MRSA is found in individuals

in the community who are generally healthy. Infections among patients with a MRSA isolate taken less than 48 hours of hospitalization is considered as CA-MRSA.¹² Our patient's infection is community-acquired considering that the cultures grew *S. aureus* taken on admission. Mortality rate associated with this organism is generally from 20-30% and depends largely on the site of infection, however, for untreated purulent pericarditis, fatality is almost certain.¹⁴ Colonization rate for CA-MRSA was reported to be at 3% of all *S. aureus* carriage and mostly identified from the anterior nares, the throat and skin folds.¹²⁻¹⁴ We suspect that our patient was already colonized with MRSA and it has gained access into the blood stream via microabrasions from the skin that may have healed and was therefore missed during the physical examination.⁸ Confirmation of patient's MRSA carriage was not carried out.

In the current antibiotic era, pediatric purulent pericarditis secondary to MRSA is rare and epidemiologic data is sparse. Once identified, treatment is centered on urgent pericardial drainage and administration of intravenous antibiotics.^{9,11} The National Antibiotic Guidelines Committee of the Philippine Department of Health recommends the use of vancomycin at 60 mg/kg/day for 3 to 4 weeks.⁹ MRSA purulent pericarditis almost exclusively occurs among individuals with predisposing factors like previous chest trauma, thoracic surgery, intrathoracic focus of infection, and those with immunocompromised states; it is seldom considered in previously healthy children with no risk factors.^{2-6,8,11} Our patient did not manifest with signs of overt immunodeficiency. He had an unremarkable past medical, personal, and family histories, and no clues suggestive of a compromised immune function. He had no history of recurrent invasive infections nor hospitalized for any infection, thus considered to be immune competent. He also remained well during the subsequent health visits after he was discharged. Thus, an immunologic investigation was deemed unnecessary. Our case clearly shows the possibility of a drug-resistant organism causing purulent pericarditis in a patient

with no predisposing condition in the epoch of antibiotics. To find similar cases, COCHRANE, EBSCO, PUBMED, MEDLINE, HERDIN databases, and locally published journals were searched. Only six similar cases were retrieved; however, of the six, only three children suffered from purulent pericarditis secondary to MRSA with no identifiable risk factors. One of these cases was found in a 2018 case report from the Journal of Pediatric Intensive Care by Sanchez et al. who described an 8-month-old infant presenting with a 10-day history of fever and cardiopulmonary distress and was successfully treated with a 2-week course of vancomycin, 5 days of daptomycin and 4 weeks of oral linezolid, while the other two cases were from an article by Lutmer et al. in the Annals of American Thoracic Society Journal where the authors reported an 8-year old male and a 7-month old female who both presented with fever and cardiopulmonary distress both effectively treated with a combination of vancomycin, gentamicin and rifampin.^{4,8} Similar to our patient, pericardial drainage was performed in all three cases, however, a 4-week course of vancomycin proved enough to effectively treat the infection in our case. Unique to our case, however, is the presence of tamponade physiology. The Philippine Pediatric Society (PPS) Disease Registry was also scoured using the ICD for infective pericarditis. The said registry does not provide the specific etiology and type of pericarditis. Since 2006, 106 cases were recorded in the country out of over 4.6 million disease cases registered; from this, only three belong to the less than 1-year old age category.¹⁵ To our knowledge, this could possibly be the first case of purulent pericarditis in a previously healthy child secondary to community-acquired MRSA to be reported in Philippine medical literature.

Our case highlights the virulence of purulent pericarditis caused by community acquired methicillin-resistant *S. aureus*. Our patient did not have any of known risk factors for *S. aureus* infection mentioned in the literatures, he was admitted from the community with a fast onset of shock and cardiopulmonary distress and clinical signs of cardiac tamponade. He survived because of prompt and

uncompromising intervention that included prompt recognition of his condition, appropriate antimicrobial therapy and pericardiostomy. Delay in the diagnosis could have resulted in the patient's demise.

SUMMARY AND CONCLUSION

We presented a case of purulent pericarditis with cardiac tamponade secondary to community-acquired MRSA in a previously healthy 10-month-old male infant presenting with fever and cardiopulmonary distress successfully treated with four-week course of vancomycin and pericardiostomy. Prompt recognition and institution of proper management led to a good outcome.

Purulent pericarditis due to community-acquired MRSA is a lethal disease that can be seen, though rarely even among immunocompetent children without predisposing factors. This highlights the presence and or rise in antibiotic-resistant organisms in the present antibiotic era, thus heralds a clarion call for antimicrobial stewardship. Our case also emphasizes the value of early recognition and prompt initiation of treatment, such as adequate drainage and the use of appropriate antibiotics. A multi-specialty team is also essential to tackle the challenges accompanying such cases.

INFORMED CONSENT

Written consent for publication of this article has been obtained from the mother of our patient.

DISCLOSURE STATEMENT

The authors declare that they have no competing interests.

ACKNOWLEDGEMENT

The authors extend their gratitude to Dr. Rogelyn Tapuro-Olais and Dr. Pearl Solimen for their support and guidance.

REFERENCES

1. Kondapi D, Markabawi D, Chu A, Gumbhir HS. Staphylococcal Pericarditis Causing Pericardial Tamponade and Concurrent Empyema. *Case Rep Infect Dis* [Internet]. 2019 Jul [cited 2021 June 21]. Available from: DOI:10.1155/2019/3701576
2. Johnson J, Cetta F. Pericardial Diseases. In: Allen D, Shaddy R, Penny D, Feltes T, Cetta F, editors. *Moss and Adams' Heart Disease in Infants and Children and Adolescents, Including the Fetus and Young Adults*. 9th edition. Philadelphia, PA:Lippincott Williams & Wilkins (LWW); 2016. p. 1428-1430.
3. Kaplan S. Infectious Pericarditis. In: Cherry J, Demmler-Harrison G, Kaplan S, Steinbach W, Hotez P, editors. *Feigin and Cherry's Textbook of Pediatric Infectious Diseases*. 8th edition. Philadelphia, PA:Elsevier; 2019. p. 270-276.
4. Lutmer JE, Yates AR, Bannerman TL, Marcon MJ, Karsies TJ. Purulent pericarditis secondary to community-acquired methicillin-resistant *Staphylococcus aureus* in previously healthy children. A sign of the times? *Ann Am Thorac Soc* [Internet]. 2013 Jan [cited 2020 Sep 16]; 10(03): 235–238. Available from: DOI: 10.1513/AnnalsATS.201211-104BC
5. Morparia K, Peshkovsky C, Kalyanaraman M. Purulent pericarditis secondary to influenza and community acquired methicillin-resistant *Staphylococcus aureus* co-infection. *Cardiol Young* [Internet]. 2018 Dec [cited 2020 Sep 16]; 28(12): 1481–1483. Available from: DOI: 10.1017/S1047951118001580
6. Abdel-Haq N, Farhat MH, Chandrasekar L, Asmar BI. Infectious and Noninfectious Acute Pericarditis in Children: An 11-Year Experience. *Int J Pediatr* [Internet]. 2018 Nov [cited 2020 Sep 16]; 2018. Available from: DOI: 10.1155/2018/5450697
7. Popovich KJ, Weinstein RA, Hota B. Are community-associated methicillin-resistant *Staphylococcus aureus* (MRSA) strains replacing traditional nosocomial MRSA strains? *Clin Infect Dis* [Internet]. 2008 Mar [cited 2020 Oct 3]; 46 (6):787–794. Available from: DOI: 10.1086/528716.
8. Sanchez J, Schneider A, Tretter J, Shopsin B, Al-Qaqa Y, Khaitan A, et al. Community-Acquired MRSA Pericarditis and Mediastinitis in a Previously Healthy Infant. *J Pediatr Intensive Care* [Internet]. 2018 Oct [cited 2020 Sep 16]; 7(2):97–101. Available from: DOI:10.1055/s-0037-1607325.
9. Department of Health (PH). National Antibiotic Guidelines Committee. *National Antibiotic Guidelines 2018*. Manila, Philippines:Department of Health; 2018. p. 56
10. Mauro P, Muratori M. Echocardiography in the diagnosis and management of pericardial disease. *J Cardiovasc Med (Hagerstown)* [Internet]. 2006 Jul [cited 2020 Sep 20]; 7 (07): 533-44. Available from: DOI: 10.2459/01.JCM.0000234772.73454.57.

11. Adler Y, Charron P, Imazio M, Badano L, Baro´ n-Esquivias G, Bogaert J, et al. 2015 ESC Guidelines for the diagnosis and management of pericardial diseases. *Eur Heart J* [Internet]. 2015 Aug 29 [cited 2020 Sep 18]. 36; 2921–2964. Available from: DOI:10.1093/eurheartj/ehv318
12. Vysakh PR, Jeya M. A Comparative Analysis of Community Acquired and Hospital Acquired Methicillin Resistant *Staphylococcus Aureus*. *J Clin Diagn Res* [Internet]. 2013 Jul [cited 2021 Jun 26]; 7(7):1339-1342. Available from: DOI: 10.7860/JCDR/2013/5302.3139
13. Creech BC, Al-Zubeidi DN, Fritz SA. Prevention of Recurrent Staphylococcal Skin Infections. *Infect Dis Clin North Am* [Internet]. 2015 Sep [cited 2021 Jun 26]. 29(3): 429–464. Available from: DOI: 10.1016/j.idc.2015.05.007.
14. Que Y, Moreillon P. *Staphylococcus aureus* (Including Staphylococcal Toxic Shock Syndrome). In: Bennett J, Dolin R, Blaser M, editors. *Mandell, Douglas, and Bennett’s Principles and Practice of Infectious Diseases*. 9th edition. Philadelphia, PA:Elsevier; 2020. P. 2393-2421.
15. Philippine Pediatric Society, Inc (PH). ICD 10 Registry [homepage on the Internet]. Quezon City, Philippines:Philippine Pediatric Society, Inc. c2020 [cited 2020 Sep 22]; [about 2 screens]. Available at: <https://pps.ivant.com/search.do>.