

[DOI]10.12016/j.issn.2096-1456.2022.08.008

· 防治实践 ·

## 口腔种植术中误吸螺丝刀病例报道及文献回顾

武霖, 孔繁芝, 钱良玉, 仇晨光, 孙洪涛, 余鹏  
江苏大学附属人民医院口腔科, 江苏 镇江(212000)

**【摘要】** 目的 探讨口腔诊疗操作中误吸、误吞的预防措施与治疗方法。方法 报道1例种植术中发生误吸的病例,并结合相关口腔诊疗操作中误吸、误吞的文献进行复习。结果 该患者行种植义齿修复时,螺丝刀不慎掉落至口中,伴随轻微咳嗽2次。手术医生及助手立即停止操作,于患者口中未寻及。患者无呼吸不畅、胸闷、气短等不适。胃镜检查未见异物,胸部X线与CT检查示左肺下叶金属致密影。局部麻醉下,呼吸内科医生使用支气管镜及配套活检钳夹取异物。取出异物后患者无明显不适,仅有轻微咳嗽,给予口服头孢氨苄、甲硝唑3 d预防感染。文献表明,口腔诊疗操作中发生误吸后应立即停止操作、放平椅位,预防异物进一步下行增加取出难度及造成消化道呼吸道损伤。通过影像学检查确定异物位置,选择相应的手段取出异物。结论 口腔诊疗操作中发生误吸、误吞后患者可能无明显不适症状,需要通过影像学检查明确异物位置后取出异物。

**【关键词】** 误吸; 误吞; 异物; 修复; 义齿; 种植牙手术; 支气管镜; 影像学检查; 螺丝刀

**【中图分类号】** R78 **【文献标志码】** A **【文章编号】** 2096-1456(2022)08-0582-06

**【引用著录格式】** 武霖,孔繁芝,钱良玉,等.口腔种植术中误吸螺丝刀病例报道及文献回顾[J].口腔疾病防治,2022,30(8):582-587. doi:10.12016/j.issn.2096-1456.2022.08.008.

**Screwdriver aspiration during implant surgery: case report and literature review** WU Lin, KONG Fanzhi, QIAN Liangyu, QIU Chenguang, SUN Hongtao, SHE Peng. Department of Stomatology, Affiliated People's Hospital of Jiangsu University, Zhenjiang 212000, China

Corresponding author: SHE Peng, Email:286486073@qq.com, Tel: 86-511-88915903

**【Abstract】 Objective** To discuss and summarize the preventive measures and treatment methods for aspiration/ingestion during dental procedures. **Methods** One case of aspiration during an implant operation was reported, and the literature on aspiration/ingestion during oral procedures was reviewed. **Results** An implant screwdriver accidentally slipped into the mouth of the patient during implant surgery. The patient experienced no obvious discomfort except a few coughs. The surgeon and assistant paused the procedure immediately to search for the screwdriver, but it was not found. The patient declared that there was no special abnormality, such as breathing disorder or chest distress, so we considered that the foreign body was ingestion. After the implant surgery was completed, no foreign body was found in the stomach via gastroscopy. Chest X-ray and CT showed a dense metal shadow in the lower lobe of the left lung. Under local anesthesia, bronchoscopy and biopsy forceps were used by respiratory physicians to clip out the foreign body. After removal of the foreign body, the patient had no obvious discomfort but a slight cough. Cephalexin and metronidazole were given for three days to prevent infection. Three days later, the patient had no complaints of respiratory discomfort. After reviewing the literature, we found that the operation should be paused immediately after aspiration/ingestion occurs during dental procedures and that the dental chair should be laid down to prevent the foreign body from descending deeper, which may increase the difficulty of removal and cause gastrointestinal and respiratory tract injury. The posi-

**【收稿日期】** 2021-12-01; **【修回日期】** 2022-02-27

**【基金项目】** 镇江市重点研发计划(社会发展)项目(SH2019060)

**【作者简介】** 武霖,主治医师,博士,Email:61802169@qq.com

**【通信作者】** 余鹏,副主任医师,博士,Email:286486073@qq.com, Tel: 86-511-88915903



微信公众号

tion of the foreign body should be determined by imaging examination, and the corresponding means to remove the foreign body should be performed. **Conclusion** Patients may have no obvious symptoms after aspiration/ingestion during dental procedures, and the foreign body can be removed after imaging examination.

**【Key words】** aspiration; ingestion; foreign body; prosthodontics; denture; implanting surgery; bronchoscope; imaging examination; screwdriver

**J Prev Treat Stomatol Dis, 2022, 30(8): 582-587.**

**【Competing interests】** The authors declare no competing interests.

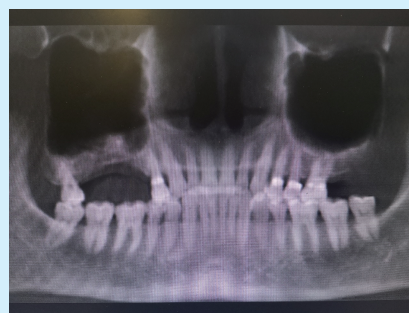This study was supported by the grants from Key Research and Development Program of Zhenjiang City (No. SH2019060).

口腔临床操作中,通常采用仰卧位,并且要求患者处于大张口状态。如未采取相关预防措施,在重力的作用下,滑脱的器械一旦掉入患者口腔,就有可能造成误吞、误吸。误吞、误吸是口腔诊疗操作中最为严重的并发症之一,容易产生医患纠纷,而且给患者带来更高的诊疗成本以及各种不适症状,甚至危及生命<sup>[1]</sup>。与误吸相比,误吞更为常见,而误吸带来的风险更高<sup>[2-4]</sup>。文献显示,在所有导致误吸的因素中,牙科相关物品排名第二(第一是进食时导致误吸)<sup>[5]</sup>。误吸往往造成剧烈的呛咳、呼吸不畅等症状,甚至造成窒息,如患者未表现出明显的呼吸道症状,较难分辨误吞或误吸。而误吸、误吞后续的治疗方案相差甚远,因此影像学检查是评判的标准,而且是做出异物取出、排入选用方式的条件<sup>[6]</sup>。本文报道1例口腔种植术中误吸后通过支气管镜取出异物的病例,并对相关文献进行回顾复习。

## 1 病例资料

患者,男,65岁。平素体健,否认吸烟、饮酒史,否认心脏病、高血压、糖尿病等系统性疾病。因牙周炎导致5颗上后牙缺如,于2019年10月在江苏大学附属人民医院口腔科行可摘活动义齿修复,后自觉戴用义齿后咀嚼功能不佳,要求种植义齿修复。口腔专科检查:15、16、17、27、28缺如,口腔卫生情况尚可,无进展期牙周炎症(图1)。

患者于2019年12月在江苏大学附属人民医院口腔科门诊手术室行种植体植入术。术前经CBCT、口内检查后,并结合经济考量及患者意愿,拟于15、17位点植入2枚种植体,27位点植入1枚种植体。手术开始后,局部麻醉、切开、剥离牙龈阶段患者无不适,使用扩孔钻时患者出现呛咳,诉冷却水进入咽喉,手术医生检查后未见明显异常,调整椅位、告知助手加强吸引器管理,并教育患者



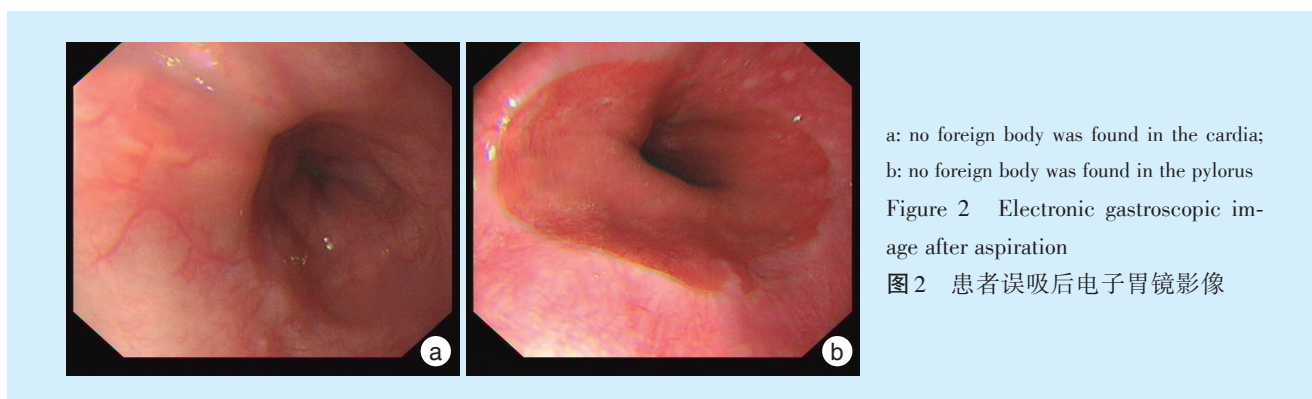
Before surgery: absence of 15-17, 27, 28

Figure 1 Panoramic image in cone-beam CT

图1 患者术前CBCT全景视图

使用鼻部呼吸。患者短暂休息后表示理解接受,术者继续进行操作。术中又有数次呛咳发生,均予短暂休息后续行操作。使用扭力扳手对愈合基台进行安装紧固时,螺丝刀不慎掉落至患者口中,伴随轻微咳嗽2次。手术医生及助手立即停止操作于患者口中寻及,但未能找到。反复询问患者有无呼吸不畅、胸闷、气短等不适,患者表示无特殊异常,且后续未表现出咳嗽等症状,故考虑异物误吞。稍事休息后,手术医生使用其他螺丝刀后继续完成安装愈合基台、缝合等后续操作。为缓解患者紧张情绪,确认异物误吞,安排助手陪同患者进行胃镜检查,结果未见异物(图2)。

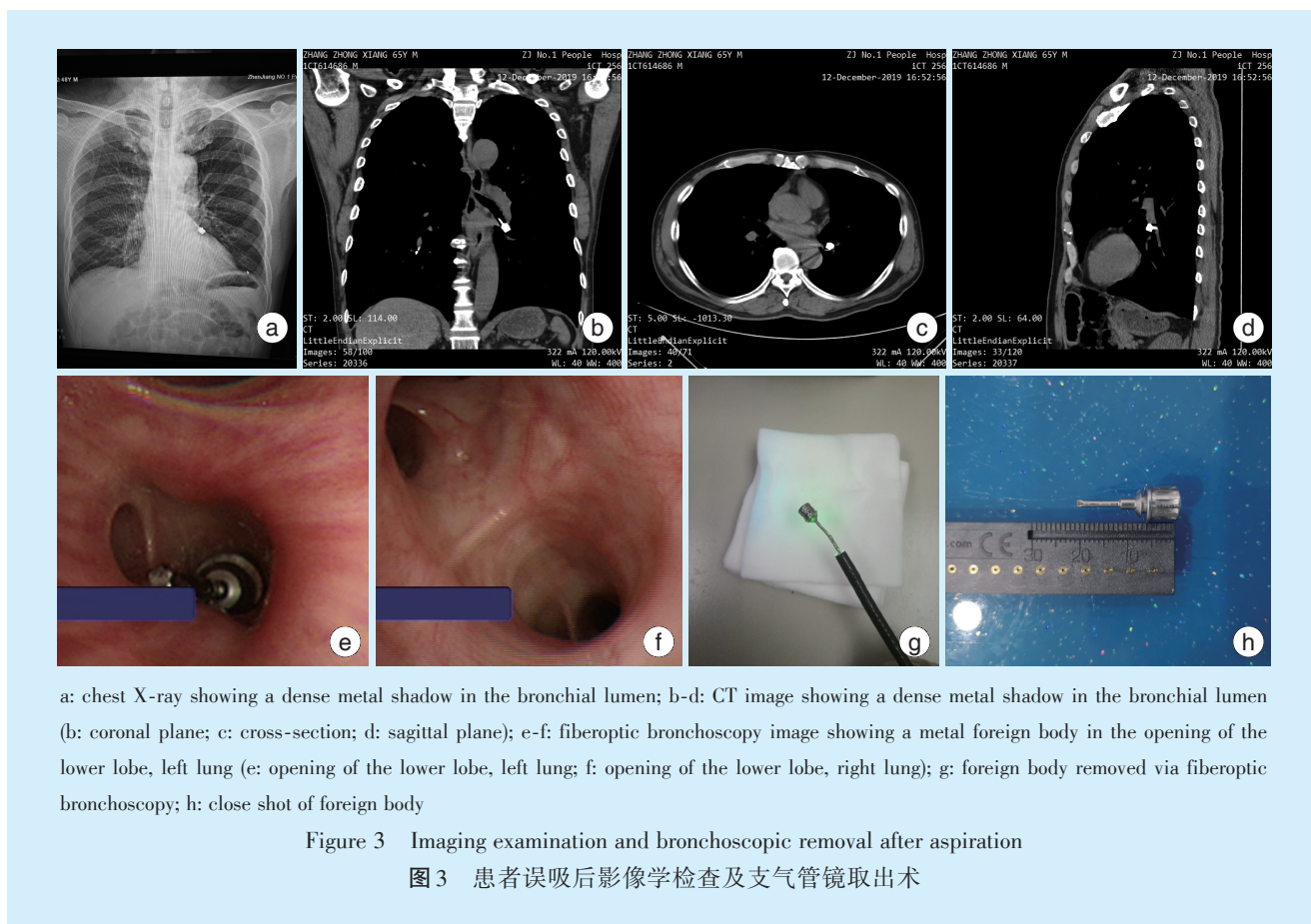
因胃镜下未见异物,故于急诊影像科行胸片检查确定异物位置。X线示左肺下叶金属致密影(图3a)。平车转运行胸部CT检查,示左肺下叶支气管腔内金属致密影(图3b~3d)。联系呼吸内科医生,局麻下进行电子支气管镜检查,镜下图像见左肺下叶开口处金属异物(图3e、3f)。局部麻醉下,呼吸内科医生使用BF-F260电子支气管镜及配套活检钳进行夹取,取出异物(图3g、3h)。取出异物后患者无明显不适,仅有轻微咳嗽,给予口服头孢氨苄(每次0.25g,4次/d)、甲硝唑3d预防感染



a: no foreign body was found in the cardia;  
b: no foreign body was found in the pylorus

Figure 2 Electronic gastroscopic image after aspiration

图2 患者误吸后电子胃镜影像



a: chest X-ray showing a dense metal shadow in the bronchial lumen; b-d: CT image showing a dense metal shadow in the bronchial lumen (b: coronal plane; c: cross-section; d: sagittal plane); e-f: fiberoptic bronchoscopy image showing a metal foreign body in the opening of the lower lobe, left lung (e: opening of the lower lobe, left lung; f: opening of the lower lobe, right lung); g: foreign body removed via fiberoptic bronchoscopy; h: close shot of foreign body

Figure 3 Imaging examination and bronchoscopic removal after aspiration

图3 患者误吸后影像学检查及支气管镜取出术

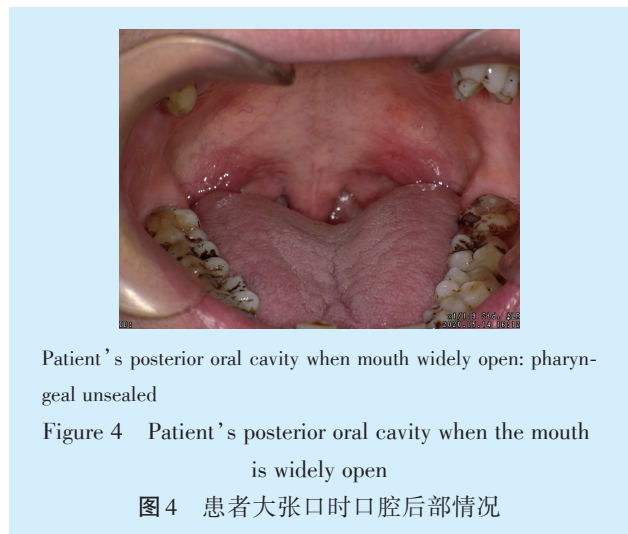
(每次0.2 g, 3次/d)。患者术后3 d均未诉有明显呼吸道不适症状。后于种植修复科继续行种植牙上部结构修复治疗。

## 2 讨论

呼吸时,会厌前上抬举,使喉腔开放;摄入食物吞咽时,会厌则向后下运动,盖住气管,防止食物液体进入气管。而口腔临床操作中,如器械掉入患者口腔前部,通常容易发现并取出;掉入口腔后部则情况相对复杂。①如患者咽反射正常,当异物触及咽后壁、舌根时,引起呕吐反射,表现为

软腭上抬,腭弓缩紧,舌根紧张。此时,异物下方咽肌收缩,阻止异物下行,异物上方咽肌松弛,咽腔扩大,便于排出异物。干呕有利于异物的自行排出,但期间无法配合医生指令,不利于医生进一步用手或工具取出异物。并且如果异物未被咳出,干呕的间隔期有可能造成异物下行进入消化道或呼吸道。②如患者咽反射较弱或消失,异物触及咽后壁患者未触发呕吐反射,一方面利于医生迅速取出异物,一方面也易造成患者不自觉吞咽或异物自然向下滑落造成误吸或误吞。③部分人群大张口时软腭、舌根未完全封闭口咽,咽腔间

隙较大,这类人群进行口腔诊疗活动需要引起重视,如果器械掉入口腔后部,极易进入咽喉下端,直接造成误吸或误吞,本例介绍的患者即属于此类型(图4)。



在口腔疾病的诊疗中,误吞、误吸罕见但亦有报道,Hisanaga等<sup>[3]</sup>统计东京牙科学院千叶医院牙科治疗过程中发生误吸、误吞的概率为0.004%,且误吸概率远小于误吞。Varho等<sup>[7]</sup>通过电子问卷统计报导芬兰分别有20.0%和6.9%的牙医报告至少有1名患者误吞、误吸了正畸物体。据Susini等<sup>[8]</sup>统计法国根管治疗中的误吸发生率为0.001/100 000,误吞发生率为0.12/100 000。对于60~79岁的患者,误吞、误吸概率较高,提示老年患者需加强警惕,临床上需主动采取措施进行预防。而就诊时焦虑恐惧、精神或智力障碍、咽反射过于强烈,以及腭部黏膜敏感性降低(咽反射消失)容易导致误吸误咽发生<sup>[9]</sup>。但全身麻醉时也有误吸病例报道,提示即使患者无自主呼吸时,仍不能排除异物进入气道的可能<sup>[10]</sup>。其他可能导致误吸、误吞的原因还有医生经验不足、患者突然过度运动、操作时光照不足、助手配合不当、患者唾液过多、操作入路困难等<sup>[11-12]</sup>。

误吸、误吞报道中最常见的异物种类为根管锉<sup>[8,11,13]</sup>、螺丝刀<sup>[14-15]</sup>、冠(桥)修复体或假牙<sup>[1,16]</sup>、钻针<sup>[12,17]</sup>、牙齿<sup>[18]</sup>、正畸附件<sup>[7,19-20]</sup>等。Tiwana等<sup>[21]</sup>认为口腔修复过程中发生误吞、误吸的概率最大。在异物误吸的统计中,掉入右侧主支气管的病例最多<sup>[9]</sup>,这可能是由于气管与右侧主支气管成角角度小、弯度小,且右侧支气管内径较粗<sup>[22-24]</sup>。但本例中,异物掉入左肺下叶支气管。随着呼吸内镜

技术的成熟,大部分误吸入支气管的异物可通过纤维支气管镜取出<sup>[25-27]</sup>。而在误吞病例中,如异物长度超过5 cm,即较难顺利通过十二指肠,建议及早通过内镜取出,否则可能导致消化道穿孔等严重的并发症,甚至需要开腹手术取出异物<sup>[28-29]</sup>。Daniels等<sup>[1]</sup>也指出误吞、误吸的早期诊断与干预治疗可降低并发症的发生概率及严重程度。

误吸、误吞并不一定伴随有特殊不适症状,若异物体积较小、圆钝光滑,相比于体积较大、长度较长、较为尖锐的异物而言,误吸、误吞后更不易引起不适,从而更不易为患者及医生觉察,影响异物第一时间取出<sup>[30]</sup>。因此,医护人员应保持警觉,一旦临床操作中材料工具丢失,就需要及时查找排除误吸、误吞可能,另外应当养成治疗结束清点器械的习惯。

国内外许多学者<sup>[31-33]</sup>对发现器械误吸、误吞后的操作进行总结,但较为芜杂,未能涵盖临床上各类复杂情况,笔者进行如下概况。①立即停止操作、放平椅位,预防器械进一步下行,以免增加取出难度及造成消化道呼吸道损伤。②如患者有呼吸道梗阻、窒息等症状,需第一时间呼叫急救,并采取海姆立克法尝试将异物冲出气道,如无效且患者出现意识不清、昏迷等情况建议及时行CPR并进行环甲膜穿刺、气管切开等应急手段;如患者感觉咳嗽、呼吸不畅,需安排吸氧并安抚患者;如患者自觉异物卡在咽喉无法吞下,立即请耳鼻喉科医生会诊,尝试通过喉镜取出异物;如在目视下能够在口腔内找到异物,可使用带齿工具钳夹取出异物。③患者如无明显症状,需进一步进行影像学检查,优先选择椅旁X线(因其移动便利)明确误吞器械的位置,如无法明确则平车移动患者,行胸腹部平片检查(有条件可选择胸腹部CT)。④判断明确异物位置后选择相关科室进行会诊:如异物位于消化道,请消化内科医生会诊,并根据异物性质、大小确定采用纤维胃镜取出或等待器械随粪便自行排出;如器械位于喉部或支气管上端,请耳鼻喉科医生会诊,并使用纤维喉镜取出异物;如器械位于支气管下端,请呼吸内科医生会诊,使用纤维支气管镜取出异物;如异物已达肺内,则需心胸外科会诊,必要时考虑开胸手术取出异物。取出异物后需影像学检查确认结果及排除残留。⑤必要时使用抗生素预防感染。

相比于误吞、误吸后进行一系列复杂繁琐的补救方法,预防措施更为关键。①每一名口腔科

医生需要了解口腔诊疗中误吞、误吸的风险,清楚地了解误吞、误吸相关并发症及法律、道德方面的问题<sup>[34]</sup>,通过培训熟悉救治流程<sup>[35]</sup>。②每位患者就诊前进行详细的检查评估,对于一些高风险病例需加强警惕(譬如本例中患者,高龄、大张口时口咽部打开),采取特殊防护措施(橡皮障<sup>[36]</sup>、调整椅位、纱布屏障保护、器械栓绳等)。③在治疗开始前、治疗中,如患者有不适、无法配合的情况,需要暂停治疗并进行告知,尽量避免强行操作增大误吞、误吸的风险。

本组病例老年患者咽反射相对减弱,在种植手术开始时即有呛咳现象,术者未充分引起重视,未对误吞、误吸风险进行再评估,未能及时采取措施加强预防。在使用螺丝刀等体积较小工具时,应栓绳固定于手部后再行操作。在误吸发生后,也未能够正确应对,依旧存在侥幸心理,未能立即停止治疗操作,仅根据患者无呼吸道症状即轻率作出异物误吞的判断。随后未采用平车转运,而是引领患者步行前往检查,未能防止异物下行,所幸及时通过影像学检查明确异物位置,并利用综合医院科室设备配套齐全的优势,通过内镜及时取出异物,避免造成更为严重的并发症。

### 3 小结

本文报道1例口腔种植术中误吸后通过支气管镜取出异物的病例,该患者大张口时口咽通道开阔,误吸后无明显主观呼吸道不适症状,极易造成临床医生判断失误,有一定的医疗安全教育意义。口腔诊疗活动中,误吞、误吸是一种罕见但存在一定风险的并发症,每位口腔医生需了解基本的预防、急救知识。一旦发生,不应心存侥幸心理,以免延误治疗带来更严重的后果。

**【Author contributions】** Wu L wrote the article. Kong FZ, Qian LY, Qiu CG, Sun HT, She P revised the article. All authors read and approved the final manuscript as submitted.

### 致 谢

在本文涉及到的咽反射、吞咽等部分内容,江苏大学附属人民医院耳鼻咽喉头颈外科的钱炜、李星星二位老师提出了建设性的意见,在此向他们表示诚挚的感谢。

### 参考文献

[1] Daniels J, Oremule B, Tsang W, et al. A 10-Year review of the

- complications caused by ingested and aspirated dentures[J]. *Ear Nose Throat J*, 2021, 100(8): 574-580. doi: 10.1177/0145561320917529.
- [2] Hodges ED, Durham TM, Stanley RT. Management of aspiration and swallowing incidents: a review of the literature and report of case[J]. *ASDC J Dent Child*, 1992, 59(6): 413-419. doi: 10.1177/00220345920710111801.
- [3] Hisanaga R, Hagita K, Nojima K, et al. Survey of accidental ingestion and aspiration at Tokyo Dental College Chiba Hospital[J]. *Bull Tokyo Dent Coll*, 2010, 51(2): 95-101. doi: 10.2209/tdcpublication.51.95.
- [4] Hisanaga R, Takahashi T, Sato T, et al. Accidental ingestion or aspiration of foreign objects at Tokyo Dental College Chiba Hospital over last 4 years[J]. *Bull Tokyo Dent Coll*, 2014, 55(1): 55-62. doi: 10.2209/tdcpublication.55.55.
- [5] Fields RT Jr, Schow SR. Aspiration and ingestion of foreign bodies in oral and maxillofacial surgery: a review of the literature and report of five cases[J]. *J Oral Maxillofac Surg*, 1998, 56(9):1091-1098. doi: 10.1016/s0278-2391(98)90263-4.
- [6] Guelfguat M, Dipoce J, Dipoce J. A dental nightmare, resolved: what a radiologist needs to know when consulted about ingestion of dental foreign body material[J]. *BJR Case Rep*, 2016, 2(2): 20150166. doi: 10.1259/bjrcr.20150166.
- [7] Varho R, Oksala H, Tolvanen M, et al. Inhalation or ingestion of orthodontic objects in Finland[J]. *Acta Odontol Scand*, 2015, 73(6): 408-413. doi: 10.3109/00016357.2014.971867.
- [8] Susini G, Pommel L, Camps J. Accidental ingestion and aspiration of root canal instruments and other dental foreign bodies in a French population[J]. *Int Endod J*, 2007, 40(8): 585 - 589. doi: 10.1111/j.1365-2591.2007.01249.x.
- [9] Hou R, Zhou H, Hu K, et al. Thorough documentation of the accidental aspiration and ingestion of foreign objects during dental procedure is necessary: review and analysis of 617 cases[J]. *Head Face Med*, 2016, 12(1): 23. doi: 10.1186/s13005-016-0120-2.
- [10] Doh RM. Foreign body aspiration during dental treatment under general anesthesia: a case report[J]. *J Dent Anesth Pain Med*, 2019, 19(2): 119-123. doi: 10.17245/jdamp.2019.19.2.119.
- [11] Obinata K, Satoh T, Towfik AM, et al. An investigation of accidental ingestion during dental procedures[J]. *J Oral Sci*, 2011, 53(4): 495-500. doi: 10.2334/josnusd.53.495.
- [12] 王水. 口腔诊疗中器械误入消化道3例报告[J]. *广东牙病防治*, 2003, 11(3): 205. doi: 10.3969/j.issn.1006-5245.2003.03.023.
- Wang S. Report of 3 cases of foreign body ingestion in dental treatment[J]. *J Dental Prev Treat*, 2003(3): 205. doi: 10.3969/j.issn.1006-5245.2003.03.023
- [13] Venkataraghavan K, Anantharaj A, Praveen P, et al. Accidental ingestion of foreign object: systematic review, recommendations and report of a case[J]. *Saudi Dent J*, 2011, 23(4): 177 - 181. doi: 10.1016/j.sdentj.2010.10.007.
- [14] El Wazani B, Nixon P, Butterworth CJ. Accidental ingestion of an implant screwdriver: a case report and literature review[J]. *Eur J Prosthodont Restor Dent*, 2018, 26(4): 184 - 189. doi: 10.1922/

- EJPRD\_01800EIWazani06.
- [15] 王菁,李东临,朱国雄.口腔诊疗过程中异物误吸一例[J].中华口腔医学杂志,2018,53(1):52-53. doi: 10.3760/cma.j.issn.1002-0098.2018.01.011.  
Wang J, Li DL, Zhu GX. A case of foreign body aspiration in oral diagnosis and treatment[J]. Chin J Stomatol, 2018, 53(1): 52-53. doi: 10.3760/cma.j.issn.1002-0098.2018.01.011
- [16] Cossellu G, Farronato G, Carrassi A, et al. Accidental aspiration of foreign bodies in dental practice: clinical management and prevention[J]. Gerodontology, 2015, 32(3): 229-233. doi: 10.1111/ger.12068.
- [17] Vincent M, Vergnon JM. Foreign body of dental origin: how to retrieve the dentist's drill?[J]. Rev Mal Respir French, 2015, 33(1): 63-66. doi: 10.1016/j.rmr.2015.06.016.
- [18] Canceill T, Esclassan R, Marty M, et al. Misdiagnosed tooth aspiration in a young handicapped boy: case report and recommendations[J]. Case Rep Dent, 2019, 2019: 8495739. doi: 10.1155/2019/8495739.
- [19] Milton TM, Hearing SD, Ireland AJ. Ingested foreign bodies associated with orthodontic treatment: report of three cases and review of ingestion/aspiration incident management[J]. Br Dent J, 2001, 190(11): 592-596. doi: 10.1038/sj.bdj.4801046.
- [20] Puryer J, Mcnamara C, Sandy J, et al. An ingested orthodontic wire fragment: a case report[J]. Dent J (Basel), 2016, 4(3): 24. doi: 10.3390/dj4030024.
- [21] Tiwana KK, Morton T, Tiwana PS. Aspiration and ingestion in dental practice: a 10-year institutional review[J]. J Am Dent Assoc, 2004, 135(9): 1287-1291. doi: 10.14219/jada.archive.2004.0404.
- [22] Worthington P. Ingested foreign body associated with oral implant treatment: report of a case[J]. Int J Oral Maxillofac Implants, 1996, 11(5): 679-681.
- [23] Ireland, AJ. Management of inhaled and swallowed foreign bodies [J]. Dent Update, 2005, 32(2): 83-86, doi: 10.12968/denu.2005.32.2.83.
- [24] Zitzmann NU, Fried R, Elsasser S, et al. The aspiration and swallowing of foreign bodies. The management of the aspiration or swallowing of foreign bodies during dental treatment[J]. Schweiz Monatsschr Zahnmed, 2000, 110(6): 619-632. doi: 10.1097/00002030-199817000-00010.
- [25] Hayashi H, Abe A, Ota M, et al. Endoscopic removal of accidental aspirated and ingested dental foreign bodies: a cross-sectional study[J]. Medicine (Baltimore), 2021, 100(46): e27602. doi: 10.1097/MD.00000000000027602.
- [26] Hajjar WM, Aljurayyad RS, Al-Jameel NI, et al. Unusual case of inhaled metallic dental bur during dental procedure in a healthy adult[J]. Saudi J Anaesth, 2016, 10(4): 465-467. doi: 10.4103/1658-354X.177324.
- [27] Leuzzi G, Kawamukai K, Lacava N. An unusual foreign body after dental filling[J]. Lung, 2013, 191(6): 677-678. doi: 10.1007/s00408-013-9514-0.
- [28] Santos Tde S, Antunes AA, Vajgel A, et al. Foreign body ingestion during dental implant procedures[J]. J Craniofac Surg, 2012, 23(2): e119-e123. doi: 10.1097/SCS.0b013e31824cda32.
- [29] Mehrabi S, Yavari Barhaghtalab MJ, Hosseinpour R. Duodenal obstruction due to accidental swallowing of a dental prosthesis: a case report and review of the literature[J]. J Med Case Rep, 2020, 14(1): 131. doi: 10.1186/s13256-020-02456-z.
- [30] Eis D, Gautschi F, Thiel S. Aspiration of an instrument during dental treatment[J]. Dtsch Arztebl Int, 2021, 118(22): 377. doi: 10.3238/arztebl.m2021.0079.
- [31] Bilder L, Hazan-Molina H, Aizenbud D. Medical emergencies in a dental office: inhalation and ingestion of orthodontic objects[J]. J Am Dent Assoc, 2011, 142(1): 45-52. doi: 10.14219/jada.archive.2011.0027.
- [32] Hill EE, Rubel B. A practical review of prevention and management of ingested/aspirated dental items[J]. Gen Dent, 2008, 56(7): 691-694.
- [33] 杨勤.口腔诊疗中异物误咽[J].口腔疾病防治,2016,24(6):321-325. doi: 10.12016/j.issn.2096-1456.2016.06.001.  
Yang Q. Ingestion of foreign body in dental treatment[J]. J Prev Treat Stomatol Dis, 2016, 24(6): 321-325. doi: 10.12016/j.issn.2096-1456.2016.06.001.
- [34] Yadav RK, Yadav HK, Chandra A, et al. Accidental aspiration/ingestion of foreign bodies in dentistry: a clinical and legal perspective[J]. Natl J Maxillofac Surg, 2015, 6(2): 144-151. doi: 10.4103/0975-5950.183855.
- [35] Umesan UK, Chua KL, Balakrishnan P. Prevention and management of accidental foreign body ingestion and aspiration in orthodontic practice[J]. Ther Clin Risk Manag, 2012, 8: 245-252. doi: 10.2147/TCRM.S30639.
- [36] Ahmad IA. Rubber dam usage for endodontic treatment: a review [J]. Int Endod J, 2009, 42(11): 963-972. doi: 10.1111/j.1365-2591.2009.01623.x.

(编辑 罗燕鸿,杨勤)



官网